

CHRONIC ALCOHOL ABUSE IS IMPLICATED IN THE OXIDATIVE STRESS AND THE CHANGES IN THE NEUROTROPHIC FACTOR RECEPTOR EXPRESSION IN THE HUMAN CNS

S. Skuja¹, V. Groma¹, R. Kleina²

¹Institute of Anatomy and Anthropology, Riga Stradins University, Riga, Latvia

²Department of Pathology, Riga Stradins University, Riga, Latvia

ABSTRACT

Alcohol abuse and alcoholism induce brain damage, and, in some cases, neurodegeneration. The pathogenesis of the alcohol-induced injury of the CNS is a complex process in which oxidative stress plays an essential role. Alcohol increases the formation of reactive oxygen species and affects the antioxidant defense system of the brain. It is well known that oxidative stress induces apoptosis in neurons, as well as in other cell types. Neurotrophins and their receptors have a crucial role in neural regulation. The aim of this study is an overall analysis of the CNS neuronal and glial cell death and the oxidative status by the use of immunohistochemical methods.

Three different CNS regions – cortical, subventricular and basal ganglia were analyzed in the autopsy samples obtained from 10 chronic alcohol abused patients. The immunohistochemical detection of oxidative damage was performed using anti-Cu/Zn SOD monoclonal antibody, neural activity – anti-NGFR (p75^{NTR}) antibody, apoptosis – the TUNEL reaction. Both, quantitative and semiquantitative estimations were used for the evaluation of results. The subventricular zone was characterized by a negative (75%) and a moderate (25%) astroglial SOD1 expression, the basal ganglia region – by strong (43%), moderate (43%), and low (14%) neuronal and moderate (71%) and low (29%) astroglial SOD1 expression, whereas, the cortex – by strong (33%) and moderate (66%) neuronal and moderate (67%), low (17%) and negative (17%) astroglial expression. The SOD1 expression was not detected in oligodendroglia and ependymocytes. Brain regions showed variability in the apoptotic cell death rates. Neuronal TUNEL-positive staining in

basal ganglia was higher than in the cerebral cortex. TUNEL-positive astrocytes were detected in the white matter, more frequently in the basal ganglia region when compared to the cortex. The apoptosis marker was nearly absent in ependymal and oligodendroglial cells. The rate of TUNEL-positive cortex endothelial cells was detected at 7.9% level in the case of chronic alcohol abuse. Neuronal processes showed heterogeneous NGFR expression: in the cortex, basal ganglia and the subventricular zone (negative/low), whereas the subcortex and the white matter – moderate and moderate/strong, accordingly. Alcohol-induced CNS vulnerability is related to the increase in oxidative stress; furthermore, it suggests an increased risk of neurodegeneration for neuronal and glial cells.

Key words: *CNS, chronic alcoholism, oxidative stress, apoptosis.*

INTRODUCTION

Experimental and post-mortem studies indicate that the most probable risk factor which induces global changes in brain morphology, is toxicity, including the chronic use of alcohol [5, 17, 19]. The basal ganglia provide a variety of functions in addition to the regulation of motor activity. The dysfunction of alcohol-abuse affected neuronal and glial cells gives rise to neurodegeneration in the basal ganglia. It has been reported that protective mechanisms, including neuronal loss, are involved in neurodegenerative disorders [9]. The programmed cell death is essential for normal tissue homeostasis. However, a chronic exposure to alcohol is the cause of increasing the amount of apoptotic cells in the striatum. Alcohol-induced oxidative stress plays a role in the pathogenesis of an injury in the central nervous system (CNS) [15]. A number of studies provided data on the changes of the nerve tissue response to the oxidative stress due to alcohol abuse. The importance of Cu/Zn superoxide dismutase (SOD1) in the CNS is confirmed by numerous findings of a protective action of this enzyme against brain injury and neuronal death [13, 10]. Recent studies [11, 14] have reported controversial results on human p75^{NTR}, also known as the low affinity nerve growth factor receptor (NGFR). It has been found to increase or inhibit the axonal growth, reduce or promote the neuronal cell death, and is necessary or not required for the inhibition of neuronal regeneration. Results on neurotrophins expression in different CNS

regions are greatly varying, experimental evidences suggest that alcohol exposure affects the expression of receptors for neurotrophic factors and impairs the production and the release of growth factors [6, 8]. The subventricular zone in the wall of the lateral ventricle is of particular interest because neurogenesis persists there during adulthood [20]. The mechanisms underlying alcohol-induced changes are unclear. The goal of the present study was to investigate alcohol-initiated morphological changes in the autopsy brain tissue by the use of immunohistochemical methods.

MATERIAL AND METHODS

The autopsy brain tissue was obtained from 10 chronic alcohol users with postmortem interval <48 h, aged 33 to 59 years according to the criteria for alcoholic cases [7]. The postmortem tissue was fixed in formalin and embedded in paraffin for routine histology. Three different CNS regions – cortical, subventricular and the basal ganglia were analyzed and compared with the brain tissue from the control non-alcoholic group. Immunohistochemical reactions were performed at sections using anti-Cu/Zn SOD monoclonal antibody (1:50, Novocastra) and anti-NGFR monoclonal antibody (1:50, DakoCytomation), apoptosis was detected by terminal deoxynucleotidyl transferase-mediated biotin-dUTP nick end labeling (TUNEL) reaction (Roche). A semiquantitative scale was used to estimate the degree of SOD1 and NGFR expression. The immunostaining was scored as follows: strongly positive, 3; moderate positive, 2; low positive, 1; and negative, 0. The percentage of TUNEL-positive cells was quantitated by counting TUNEL positive and negative cells in 10 random microscope fields. All the tissue sections were analyzed using a Leica microscope (x400). Study procedures were conducted in accordance with the rules of the Ethical Committee.

RESULTS

Semiquantitative evaluation revealed the following percentages of low, moderate and strong expression of SOD1: 14% low, 43% moderate, 43% strong in the basal ganglia neurons; 29% low and 71% moderate in the basal ganglia astroglial cells (Figure 1), whereas the cortex was

characterized by moderate (67%) and strong (33%) neuronal SOD1 expression; moderate (66%), low (17%) and negative (17%) astroglial SOD1 expression. In comparison, the neurons of the control group and, particularly, astrocytes showed a low SOD1 expression. The white matter showed low (50%) and moderate (50%) astroglial SOD1 expression, and moderate SOD1 expression in neuronal processes (Figure 2), whereas the control group showed negative or occasionally low astroglial and neuronal processes SOD1 expression. The sub-ventricular zone showed negative (75%) and moderate (25%) astroglial SOD1 expression, whereas the control group showed scattered SOD1 positive astrocytes. Negative SOD1 expression is revealed in ependimocytes and oligodendrocytes (Table 1).

Neuronal TUNEL-positive staining in the basal ganglia (Figure 3) was higher than in the cerebral cortex. TUNEL-positive astrocytes were detected in the white matter, more frequently in the basal ganglia region than in the cortex. TUNEL-positive staining in the brain tissue in the cases of chronic alcoholism compared with the control group was significantly higher. Apoptosis was not detected in oligodendroglia (Figure 4) and was almost zero in the ependyma. The apoptosis of endothelial cells was also detected within the vascular beds. The percentage of TUNEL-positive cortex endothelial cells varied from 2.88% up to 10.46% in the cases of chronic alcoholism.

Neuronal processes showed heterogeneous NGFR expression in the cortex, subcortex and basal ganglia regions (Table 2). The axons of the basal ganglia neurons demonstrated negative or low NGFR expression, whereas the white matter showed moderate or strong expression (Figure 5). The cortex showed negative or low, whereas the subcortex – moderate NGFR expression (Figure 6). NGFR expression in the sub-ventricular zone was negative or low.

Table 1. Occurrence and distribution of SOD1 expression in alcohol users

Nr	Subventricular zone			Subcortex						Cortex		
	ependyma	pro- cesses	astro-	Basal ganglia			White matter			astro-	oligo-	neuro-
asto-				oligo-	neuro-	pro- cesses	astro-	oligo-				
1				2	0	3	1/2	0/1	0			
2				2	0	3	1/2	0/1	0			
3				2	0	2	2	2	0	2	0	2/3
4				2	0	3	1	0/1	0			
5							0/1	2	0	2	0	2/3
6	0	0	0	0/1	0	2	3	0/1	0	0/1	0	1/2
7	0	2	2				1	0/1	0	0	0	1/2
8	0	0	0				1/2	1/2	0	1/2	0	1/2
9	0/1	1/2	0				1/2	1/2	0	2	0	1/2
10				2	0	1/2	2/3	2	0			

Table 2. Occurrence and distribution of NGFR expression in alcohol users

Nr	Basal ganglia	White matter/ basal ganglia	Subventricular area	Cortex	White matter/ subcortex
1	1	3			
2	1	2/3			
3				0/1	0/1
4	0/1	2/3			
5			0	0	2/3
6			0	0	3
7		1/2	0	0/1	1
8	0	1/2	1		
9				0	2
10	1	3	0/1		

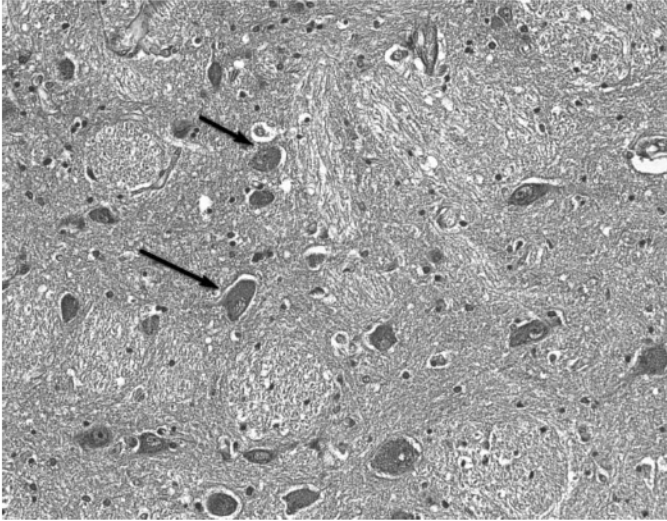


Figure 1. SOD1 immunopositive neurons (black arrows) in the basal ganglia region. Original magnification x250.

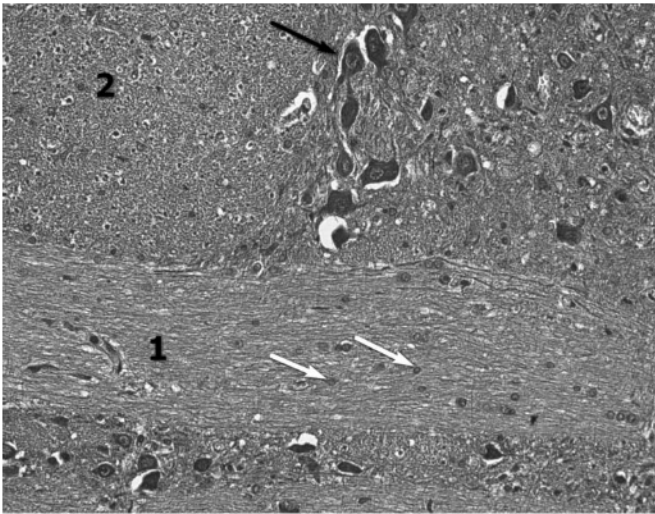


Figure 2. SOD1 immunonegative oligodendroglia (white arrows) in the white matter (1), SOD1 immunopositive neurons (black arrow) in the cortex (2). Original magnification x250.

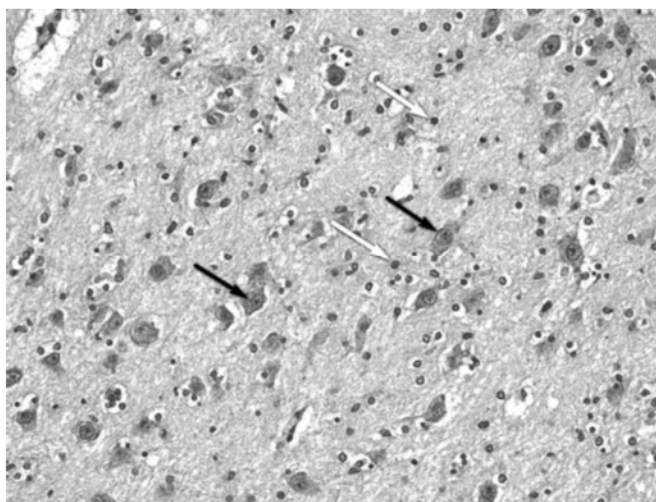


Figure 3. TUNEL-positive astrocytes (white arrows) and TUNEL-positive neurons (black arrows) in the basal ganglia region. Original magnification x250.




Figure 4. TUNEL-negative oligodendroglia (white arrowheads) in the white matter (1), TUNEL-positive (black arrows) and astrocytes (black arrowhead) and TUNEL-negative (white arrow) neurons in the cortex. Original magnification x400.

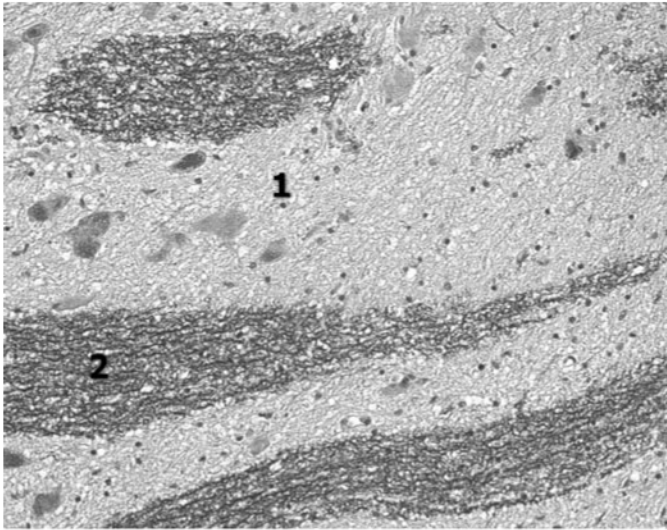


Figure 5. Negative NGFR expression in the basal ganglia (1) and strong expression in the white matter (2). Original magnification x250.

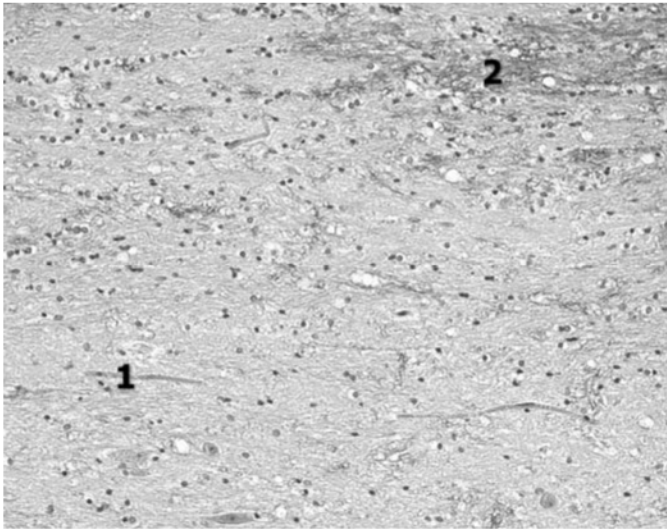


Figure 6. Low NGFR expression in the cortex (1) and moderate in the subcortex (2). Original magnification x250.

DISCUSSION

Cu/Zn superoxide dismutase, which is a key antioxidant enzyme, is present in the central and peripheral nervous systems [3, 12, 22], however, the cellular and intracellular localizations of SOD1 are not well defined. Our data suggest that SOD1 is strongly expressed in neurons, and to a lesser extent – in neuroprotective astrocytes. The highest expression of SOD1 enzymes is observed in the basal ganglia neurons, and it may be caused by the motor system vulnerability underlying chronic alcohol exposure. Moderate or low expression of antioxidant enzymes in the basal ganglia astrocytes suggests an increased activity of the nerve tissue protective system. Alcohol related changes are characterized by the increased expression of SOD1 in neurons paralleled by moderate or low, and even negative enzymatic protection in the astroglial cells of cortical regions, providing additional information on nerve tissue response to oxidative stress. This study evidenced the lowest subventricular expression of astroglial SOD1 suggesting poor reactivity within a region responsible for potential neurogenesis. Occasionally, antioxidant enzyme immunoreactivity was observed in the ependymal cells of lateral ventricles.

Cortical, subcortical and basal ganglia regions show variability in the apoptotic cell death rates [4]. TUNEL-positive staining is significantly higher in the brain tissue in the cases of chronic alcoholism compared with the control group. TUNEL-positive staining in all the cases of alcohol abuse identified the cell types which are the targeted for alcohol toxicity. Our findings suggest that the programmed cell death of both neurons and astrocytes is enhanced in the cortex and the basal ganglia regions. Our observations are in accordance with the recent studies [2, 16] and confirm a high TUNEL-positive neuronal staining in the cerebral cortex associated with the loss of brain volume. TUNEL-positive astrocytes were most frequently detected in the white matter in subcortical regions. Neurons and astroglial cells are sensitive to alcohol consumption, which promotes an apoptotic pathway of neurodegeneration. Endothelial cell apoptosis allows considering a possibility of the blood-brain barrier disfunction [18]. Despite the fact that the alcohol-induced oligodendroglial cell death has been reported previously [1], we were unable to confirm oligodendroglial damage underlying alcohol consumption.

The number of neurons bearing low affinity p75 neurotrophin receptor is higher in the alcohol abuse cases compared to the control group. Our observations of significantly elevated expression of NGFR in the white matter of the basal ganglia region, chronically affected by alcohol, are in accord with the previous work [21]. Whilst cortical regions show the increased activity of antioxidative enzymes and the TUNEL-positive staining of neuronal cells, p75 neurotrophin receptor expression appears to be negative in the cortex and moderate in subcortical axons. A decreased p75 neurotrophin receptor expression may be suggestive of the cell damage occurring in the brain tissue [23].

REFERENCES

1. Casha S., Yu W.R., Fehlings M.G. (2001) Oligodendroglial apoptosis occurs along degenerating axons and is associated with FAS and p75 expression following spinal cord injury in the rat. *Neuroscience*, 103, 1, 203–218.
2. Crews F.T., Nixon K. (2008) Mechanisms of Neurodegeneration and Regeneration in Alcoholism. *Alcohol and Alcoholism*, 44, 2, 115–127.
3. Culotta V.C., Yang M., O'Halloran T.V. (2006) Activation of superoxide dismutases: Putting the metal to the pedal. *Biochim Biophys Acta*, 1763, 7, 747–758.
4. Fein G., Di Sclafani V., Cardenas V.A., Goldmann H., Tolou-Shams M., Meyerhoff D.J. (2002) Cortical gray matter loss in treatment-naïve alcohol dependent individuals. *Alcohol Clin Exp Res*, 26, 4, 558–564.
5. Finkel T., Holbrook N.J. (2000) Oxidants, oxidative stress and the biology of ageing. *Nature*, 408, 6809, 239–247.
6. Gericke C.A., Schulte-Herbrüggen O., Arendt T., Hellweg R. (2006) Chronic alcohol intoxication in rats leads to a strong but transient increase in NGF levels in distinct brain regions. *Journal of Neural Transmission*, 113, 7, 813–820.
7. Harper C., Dixon G., Sheedy D., Garrick T. (2003) Neuropathological alterations in alcoholic brains. Studies arising from the New South Wales Tissue Resource Centre. *Prog Neuropsychopharmacol Biol Psychiatry*, 27, 6, 951–961.
8. Heaton M.B., Paiva M., Madorsky I., Mayer J., Moore D.B. (2003) Effects of ethanol on neurotrophic factors, apoptosis-related proteins, endogenous antioxidants, and reactive oxygen species in neonatal

- striatum: relationship to periods of vulnerability. *Brain Res Dev Brain Res*, 140, 2, 237–252.
9. Ikegami Y., Goodenough S., Inoue Y., Dodd P.R., Wilce P.A., Matsumoto I. (2003) Increased TUNEL positive cells in human alcoholic brains. *Neuroscience Letters*, 349, 3, 201–205.
 10. Johnson F., Giulivi C. (2005) Superoxide dismutases and their impact upon human health. *Molecular Aspects of Medicine*, 26, 4–5, 340–352.
 11. Johnston A.L., Lun X., Rahn J.J., Liacini A., Wang L., Hamilton M.G., Parney I.F., Hempstead B.L., Robbins S.M., Forsyth P.A., Senger D.L. (2007) The p75 neurotrophin receptor is a central regulator of glioma invasion. *PLoS Biology*, 5, 8, e212.
 12. Lindenau J., Noack H., Possel H., Asayama K., Wolf G. (2000) Cellular distribution of superoxide dismutases in the rat CNS. *Glia*, 29, 25–34.
 13. Maier C.M., Chan P.H. (2002) Role of Superoxide Dismutases in Oxidative Damage and Neurodegenerative Disorders. *The Neuroscientist*, 8, 4, 323–334.
 14. Mamidipudi V., Wooten M.W. (2002) Dual role for p75NTR signaling in survival and cell death: Can intracellular mediators provide an explanation? *Journal of Neuroscience Research*, 68, 4, 373–384.
 15. Peluffo H., Acarin L., Faiz M., Castellano B., Gonzalez B. (2005) Cu/Zn superoxide dismutase expression in the postnatal rat brain following an excitotoxic injury. *Journal of Neuroinflammation*, 2, 1, 12.
 16. Pfefferbaum A., Sullivan E.V. (2005) Disruption of brain white matter microstructure by excessive intracellular and extracellular fluid in alcoholism: evidence from diffusion tensor imaging. *Neuropsychopharmacology*, 30, 2, 423–432.
 17. Przedborski S., Vila M., Jackson-Lewis V. (2003) Neurodegeneration: What is it and where are we? *The Journal of Clinical Investigation*, 111, 1, 3–10.
 18. Shiu C., Barbier E., Di Cello F., Choi H.J., Stins M. (2007) HIV-1 gp120 as Well as Alcohol Affect Blood–Brain Barrier Permeability and Stress Fiber Formation: Involvement of Reactive Oxygen Species, Alcoholism: Clinical and Experimental Research, 31, 1, 130–137.
 19. Tateno M., Saito T. (2008) Biological studies on alcohol-induced neuronal damage. *Psychiatry Invest*, 5, 21–27.
 20. Taupin P., Gage F. H. (2002) Adult neurogenesis and neural stem cells of the central nervous system in mammals. *Journal of Neuroscience Research*, 69, 6, 745–749.
 21. Toesca A., Giannetti S., Granato A. (2003) Overexpression of the p75 neurotrophin receptor in the sensori-motor cortex of rats exposed to

- ethanol during early postnatal life. *Neuroscience Letters*, 342, 1–2, 89–92.
22. Viggiano A., Viggiano D., Viggiano A., De Luca B. (2003) Quantitative histochemical assay for superoxide dismutase in rat brain. *J Histochem Cytochem*, 51, 7, 865–871.
23. Yuan J., Yankner B.A. (2000) Apoptosis in the nervous system. *Nature*, 407, 6805, 802–809.

Address for correspondence

Sandra Skuja
Laboratory of Electron Microscopy
Institute of Anatomy and Anthropology
Kronvalda blv 9, Riga, LV-1010, Latvia
E-mail: sandra.skuja@gmail.com