

CASE REPORT

Methicillin Susceptible Panton –Valentine Leukocidin Positive *S. Aureus* Pneumonia in a Child with Novel Influenza H1N1 Infection

Liene Cupane*/**, Nina Pugacova*, Girts Aleksejevs*, Dace Berzina**/**, Dace Gardovska*/**, Edvins Miklasevics**/**

*Children's Clinical University Hospital, Riga, Latvia

** Pauls Stradins Clinical University Hospital, Riga, Latvia

***Riga Stradins University, Department of Paediatrics, Latvia

Summary

The first case in Latvia of Panton – Valentine leukocidin (PVL) positive methicillin susceptible *Staphylococcus aureus* (MSSA) pneumonia in an adolescent with novel influenza A H1N1 is described.

A 15 year old boy was admitted to intensive care suffering from severe respiratory failure with bilateral necrotic pneumonia. The presence of influenza A H1N1 was confirmed by PCR. Invasive *S. aureus* was spa type t435 and Panton–Valentine leukocidin gene positive. He received therapy with ceftriaxone, oxacillin, clindamycin and oseltamivir phosphate and underwent two chest operations. He was discharged after 58 days in hospital.

Key words: H1N1, *S. aureus*, PVL; MSSA.

AIM OF THE DEMONSTRATION

Novel influenza type A (H1N1), or pandemic flu was first identified in April 2009 in Mexico and rapidly worldwide. On 11 June, 2009 the World Health Organization formally confirmed H1N1 influenza pandemic. The course of illness was mild or moderate in most cases and hospitalization due to severe influenza was required mainly for persons from the following risk groups: children under 2, pregnant women those with underlying chronic disease and the immunocompromised (14).

In Latvia the novel pandemic influenza A/ H1N1 virus was first identified in June 2009; and new cases appeared sporadically until November when more than 50 new cases of pandemic flu were identified per week (15). During the period 20 – 26 November, 2009, very high activity was reported in Europe including Latvia, with children up to 15 years of age affected to unusually high degrees (16).

Uncomplicated human influenza virus infection causes transient tracheo – bronchitis due as the virus attaches to tracheal and bronchial epithelial cells. The main complication is extension of viral infection to the alveoli often complicated with bacterial infection resulting in severe pneumonia. Necrotizing *S. aureus* pneumonia has long been recognized, but the association with PVL was made less than ten years ago. PVL positive *S. aureus* necrotising pneumonia is often lethal and can follow respiratory infections, especially influenza. Numerous cases since have been reported worldwide. Panton – Valentine Leukocidin is a bicomponent pore-forming *S. aureus* exotoxin which mainly acts on neutrophils. PVL producing *S. aureus* may be either methicillin sensitive or

resistant, however mainly associated with community acquired methicillin resistant *S. aureus*.

Here, we report the first case in Latvia of methicillin susceptible Panton – Valentine leukocidin (PVL) positive *S. aureus* severe pneumonia in an adolescent with influenza A H1N1.

CASE REPORT

A 15 – year old boy was admitted to Daugavpils Regional Hospital on the evening 29 November 2009 with a 4 day history of low-grade to high fever, vomiting and a dry cough with haemoptysis and discomfort behind the sternum on the day of the hospitalization.

A chest X-ray, performed on admission, showed total right sided pneumonia, the patients' CRP (C- reactive protein) was 253,65 mg/l (N 0–7,9 mg/l) with other indicators as follows: HGB 15,8 g/dl, RBC – 5,56 x10⁶ (N 4,5–5,3), WBC – 7,5x10³ (N 4,5–13), PLT 160 x10³ (N 181–521). A nasopharyngeal swab was taken to detect respiratory viruses. Empiric antibacterial therapy with ceftriaxone and metronidazole was commenced. After a few hours the patient was moved to the intensive care unit and subsequently to the main children's hospital due to his progressive respiratory insufficiency. On the morning of November 30 the patient was transferred to the Childrens Clinical University Hospital (CCUH) in Riga. On arrival at CCUH, Riga, the patient had difficulty breathing and had signs of severe respiratory failure; he was sitting in an enforced position, had tachypnea (35 – 40 times per min.) with loud, groaning breathing and intercostal retractions and his blood pressure was raised (200/87 mmHg). Auscultation of the lungs showed unilateral dullness on the right side.

The chest X-ray showed multiple focal shadows on both sides of the lungs and unilateral intensive infiltration in the middle part of the right lung that suggested severe bilateral pneumonia (Pict. 1). Laboratory findings showed significant changes in blood gases – decreased pO_2 – 70,6 mmHg (N 71–104 mmHg), increased pCO_2 – 78,6 mmHg (N 32–46 mmHg), base excess was 6 mmol/l (N –5 – 5), pH – 7,28 (N 7,37–7,45) and still elevated CRP – 261,65 mg/l, urea and creatinine levels were normal. His blood count at admission was normal except of “left shift” with 1% of metamyelocytes.

His history was unremarkable except miozitis after acute respiratory infection in January, 2008 and recurrent faringitis in the summer 2008.

He was admitted to the intensive care unit and empiric oral antiviral therapy with oseltamivir phosphate (75mg twice daily) and intravenous antibacterial therapy with ceftriaxone and oxacillin in addition to antihypertensives and symptomatic therapy were commenced. One day later clindamycin was added.

Novel influenza A H1N1 infection was confirmed by PCR and *S. aureus* isolated from blood and pleural fluid on the day of admission were methicillin susceptible, Pantone – Valentine leukocidin producing and were *spa* type *t435*. Antibacterial susceptibility was determined according to CLSI standards (M2–A9, M100–S16). The *lukSF*–PV genes were detected by PCR (4). Chromatograms of the *spa* sequences were analysed by Ridom StaphType software (Ridom GmbH).

Blood analyses that were taken two days later showed elevated inflammatory markers interleukin 6 (Il6) was 172 pg/ml (N <10 pg/ml) and calcitonin prohormone procalcitonin (PCT) level 2– 10 ng/ml (N< 0,5 ng/ml). Eleven hours after admission due to increasing respiratory insufficiency mechanical pulmonary ventilation was started and continued for 15 days. The general condition of the patient remained severe for more than five days.

On the 16th day the boy underwent operative therapy with a right side thoracotomy and resection of S4, S5 of the right lung (Pict.2) because of the severe condition due to pneumothorax and empyema. Further investigations of postoperative material revealed necrosis and inflammation of lung tissues. After the operation his general condition improved and it was decided to continue conservative therapy with antibiotics, but due to a post operative fistula of the right lung, the surgery was repeated after 3 weeks and the fistula was closed. The patient underwent repetitive bronchoscopies and antibacterial therapy with ceftriaxone (14 days), oxacillin (14 days), clindamycin (21 days) and oseltamivir phosphate (5 days). With this treatment blood cultures became negative on the 14th day of hospitalization. His general condition improved and after 58 days in hospital the patient was discharged.

DISCUSSION

Bacterial infection with *Staphylococcus aureus* is a known cause of severe illness often occurring after, and complicating, viral respiratory infection (9, 17). *In vitro* *S. aureus* will adhere mainly to poorly differentiated

airway epithelial cells, confirming its tropism for injured and remodelled airway epithelium (7).

Pantone – Valentine leukotoxin (PVL) is a pore forming staphylococcal γ toxin encoded by the *lukSF*–PV genes (10), and is associated with skin abscesses and necrotizing pneumonia (6). Pneumonia often arises from the blood born spread of organisms from infected tissues and can follow viral respiratory infections, especially influenza (8). From 2002–3 isolates it has been estimated that <2% of *S. aureus* in the UK were PVL positive, most were methicillin sensitive, with 65% of them associated with skin and soft tissue infections, 17% with pneumonia (3). Gillet *et al* (1) compared the clinical features of PVL positive and PVL negative pneumonias and found in contrast to PVL–negative pneumonia patients, those with PVL–*S. aureus* were younger and mostly immunocompetent. They presented with influenza like symptoms, high fever, tachycardia, tachypnoe, haemoptysis and bilateral infiltrates, and pleural effusion more often. Other case series confirm the characteristics and severity of PVL – positive infections. (7,4,5,11). The symptoms of the described patient were equal with the described features.

Combined empirical antibacterial therapy of wide spectrum antibiotics is used in life–threatening infections. We used ceftriaxone and oxacillin empirically to treat atypical pneumonia in addition to antiviral therapy with oseltamivir phosphate (12). Oseltamivir phosphate was started due to possibility of influenza infection and severe condition of patient (18). Due to a rapidly worsening general condition and changes in the chest X–ray which was similar to PVL caused pneumonia, clindamycin was added one day after the initial therapy. International guidelines not been published for the therapy of necrotising pneumonia caused by PVL positive *S. aureus*, however some local guidelines do exist (19), and mostly recommend the use of protein synthesis inhibiting antibiotics including clindamycin – when guided by *in vitro* susceptibility results. In addition, several publications recommend the addition of clindamycin in the treatment of toxin producing Gr+ bacteria as it may reduce toxin production (13).

Besides conservative therapy, surgery was also used due to the patients severe condition after two weeks, treatment with broad spectrum antibiotics and intensive care therapy. There is controversy over the indications and best timings for surgery in cases of pulmonary necrosis, especially in children. In our case the operation was done successfully despite the postoperative fistula, after the lobectomy, which prolonged the patients stay in hospital.

PVL positive *S. aureus* with *spa* type *t435* are mostly methicillin susceptible and are spread in Latvia with sporadic cases in Poland, Austria, Romania and Hungary (2). In Latvia PVL positive *S. aureus* with *spa* type *t435* is spread among children with purulent skin and soft tissues infections (Cupane, in preparation).

Our described case exposes that PVL – positive *S. aureus* with *spa* type *t435* can complicate influenza in otherwise healthy children, with rapid progression to

severe pneumonia that needs complicated and long management of the illness.

Conflict of interest: None

REFERENCES

- Gillet Y, Issartel B, Vanhems P, Fournet JC, Lina G, Bes M, et al. Association between *Staphylococcus aureus* strains carrying gene for Panton – Valentine leukocidin and highly lethal necrotising pneumonia in young immunocompetent patients // *Lancet*, 2002; 359: 753 – 759
- Grundmann H, Aanensen DM, van den Wijngaard CC, Webster C, Tami A, Feil EJ, et al. // *PLoS Med*, 2010 ; 12: 7(1)
- Holmes A, Ganner S, McGuane S, Pitt TL, Cookson BD, Kearns AM. *Staphylococcus aureus* isolates carrying Panton – Valentine leucocidin gene in England and Wales: frequency, characterization, and association with clinical disease // *J Clin Microbiol*, 2005; 5: 2384. – 2390
- Hussain A, Robinson G, Malkin J, Duthie M, Kearns A, Perera N. *Purpura fulminans* in a child secondary to Panton – Valentine leukocidin – producing *Staphylococcus aureus* // *J Med Microbiol*, 2007; 56: 1407– 1409
- Kravitz GR, Dries DJ, Peterson ML, Schlievert PM. *Purpura fulminans* due to *Staphylococcus aureus* // *Clin Infect Dis*, 2005; 40: 941–947
- Lina G, Piemont Y, Godail–Gamot F, Bes M, Peter MO, Gauduchon V, et al. Involvement of Panton– Valentine leukocidin–producing *Staphylococcus aureus* in primary skin infections and pneumonia // *Clin Infect Dis*, 1999; 29:1128–1132
- Mongodin E, Bajorel O, Hinnarsky J, Puchelle E, de Bentzmann S. Cell wall–associated protein A as a tool for immunocolonization of *Staphylococcus aureus* in infected airway epithelium // *J Histochem Cytochem*, 2000; 48: 523 – 534
- Morgan M. *Staphylococcus aureus*, Panton – Valentine leukocidin, and necrotising pneumonia // *BMJ*, 2005; 331: 793 – 794
- Peltola VT, McCullers JA. Respiratory viruses predisposing to bacterial infections: role of neuraminidase // *Pediatr Infect Dis J*, 2004; 23: 87– 97
- Prevost G, Mourey L, Colin DA, Menestrina G. *Staphylococcal* pore – forming toxins // *Microbiol Immunol*, 2001; 257: 58 – 83
- Roberts JC, Gulino SP, Peak KK, Luna VA, Sanderson R. Fatal necrotizing pneumonia due to a Panton – Valentine leukocidin positive community–associated methicillin – sensitive *Staphylococcus aureus* and Influenza co– infection: a case report // *Ann of Clin Microbiol Antimicrob*, 2008; 7: 5
- Sectish TC, Prober CG. Chapter 397 – Pneumonia // In Kliegman RM, Behrman RE, Jenson HB, Stanton BF. *Nelson Textbook of Pediatrics*. 18th ed. Philadelphia: Saunders Elsevier; 2007; 1795 – 1799
- Stevens DL, Ma Y, Salmi DB, McIndoo E, Wallace RJ, Bryant AE. Impact of Antibiotics on Expression of Virulence–Associated Exotoxin Genes in Methicillin–Sensitive and Methicillin–Resistant *Staphylococcus aureus* // *J Infect Dis*, 2007; 195: 202– 211
- Who is more at risk of severe illness? What about other risks? [WHO web site] 24 February 2010. Available at: http://www.who.int/csr/disease/swineflu/frequently_asked_questions/risk/en/index.html Accessed April 10, 2010
- Results of laboratory confirmed cases of novel influenza A H1N1. [Infectology Center of Latvia web site] Available at: http://www.lic.gov.lv/docs/268/2010/jauna%20gripa_LIC_16012010.pdf Accessed April 16, 2010
- High pandemic (H1N1) 2009 activity, particularly in children. WHO/Europe outbreak update, 30 November 2009. Available at: http://www.euro.who.int/influenza/AH1N1/20091202_1 . Accessed April 16, 2010
- Surveillance for Pediatric Deaths Associated with 2009 Pandemic Influenza A (H1N1) Virus Infection– United States, April–August 2009, September 4, 2009 / Vol. 58 / No. 34 / Pg. 941 – 968 Morbidity and mortality weekly report, CDC
- WHO Guidelines for Pharmacological Management of Pandemic (H1N1) 2009 Influenza and other Influenza Viruses [WHO web site]. February 2010. Available at: http://www.who.int/csr/resources/publications/swineflu/h1n1_use_antivirals_20090820/en/index.html Accessed April 16, 2010
- Health Protection Agency. Revised guidance on the diagnosis and management of PVL–associated *Staphylococcus aureus* infections (PVL–SA) in the UK. [HPA web site] 2008 Available at: http://www.hpa.org.uk/PVL-SA_FinalGuidance.pdf

Address:

Liene Cupane,
Riga Stradins University, Department of Paediatrics
Vienibas gatve 45
LV-1004 Riga, Latvia
E-mail: lcupane@tvnet.lv

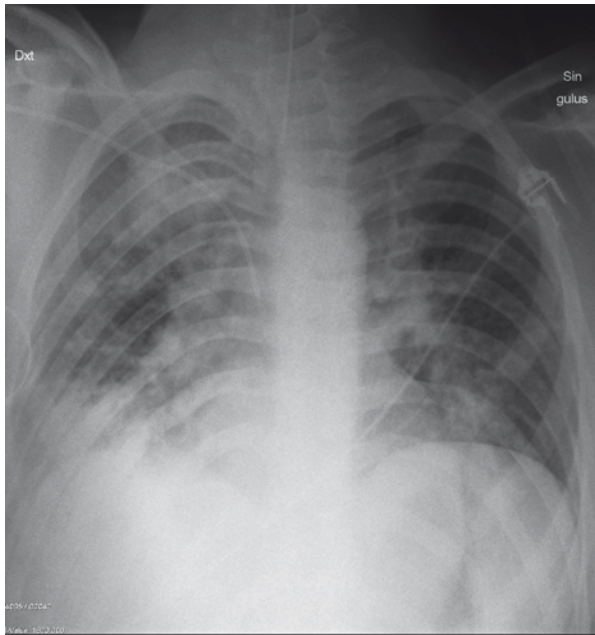


Fig. 1. Chest X-ray on admission with multiple focal shadows on the both sides of the lungs and unilateral intensive infiltration in the middle part of the right lung that suggested the severe bilateral pneumonia

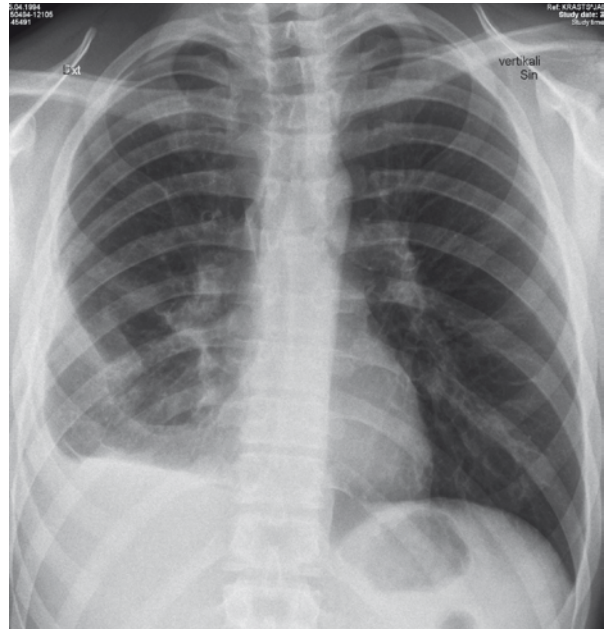


Fig. 2. Chest X-ray when the patient was discharged after resection of middle part of the right lung with clinical improvement