

# Radiographic assessment of findings in the maxillary sinus using cone-beam computed tomography

*Ilze Dobele, Ligija Kise, Peteris Apse, Gints Kragis, Andris Bigestans*

## SUMMARY

**Objectives.** To assess the presence of anatomic variations and pathology of the maxillary sinus using cone beam computed tomography (CBCT) of the maxilla where pre-implant surgery is planned.

**Material and methods.** This retrospective study evaluates a sample CBCT scans of 34 dental patients (68 sinuses). CBCT is used to assess maxillary sinus mucosa and outflow and prevalence of septa. The mucosal thickening was measured and the sinus outflow was classified as open or obstructed.

**Results.** Mucosal thickening was found in 48.5%, septa in 20.6% and total opacity in 2.9% of the sinuses. Maxillary sinus outflow was blocked in 26.5% of the scans. Strong association between radiological signs of maxillary sinus ostium blockage and thickened mucosa was observed.

**Conclusions.** Anatomic variations and lesions of the maxillary sinus were common findings in CBCT examinations of the maxilla required for dental preprosthetic planning. Routine CBCT scans, including maxillary sinus ostium are recommended for risk assessment prior to surgery.

**Key words:** cone beam computed tomography, maxillary sinus, mucosal thickening, dental implants, and sinus floor elevation.

## INTRODUCTION

The maxillary sinus is the paranasal sinus that impacts most on work of the dentists and the maxillofacial surgeon when treatment requires bone grafting in this area. Augmentation of the maxillary sinus floor is well-documented and considered a conventional procedure, which allows the rehabilitation of the atrophic posterior maxilla using osseointegrated dental implants (1). Computerized tomography is considered a gold standard for sinus diagnosis and planning surgery (2, 3). A conceptual understanding of the anatomic and functional relationships

between the maxillary sinus and upper posterior teeth is important when dealing with chronic inflammatory diseases and surgery planning. A significant difference in the bone height of the sinus floor exists between dentulous and edentulous individuals. In persons with maxillary tooth loss, pneumatization combined with ridge atrophy leaving thin alveolar bone or only mucoperiosteum (Schneiderian membrane) between the sinus floor and oral cavity (4). The placement of the dental implants in such patients requires preprosthetic surgical procedures such as alveolar bone grafting and sinus floor elevation. Providing dental implants to patients who have lost upper posterior teeth and surrounding bone requires radiological assessment of the planned implant site. The opening of the maxillary sinus osteomeatal complex (OMC) is located high in the medial sinus wall. Compromised maxillary sinus drainage system is associated with a higher risk of postoperative sinusitis, and is a significant area in examining patient with sinus complaints, there may be a justification to extend the field of view (FOV) to include the whole of the maxillary sinus including the OMC. This information allows assessing

<sup>1</sup>Department of Otolaryngology, Riga Stradins University, Latvia

<sup>2</sup>Department of Prosthetic Dentistry, Riga Stradins University, Latvia

<sup>3</sup>Department of Oral and Maxillofacial Surgery, Riga Stradins University, Latvia

*Ilze Dobele*<sup>1</sup> – M.D., Dip Otolaryngologist

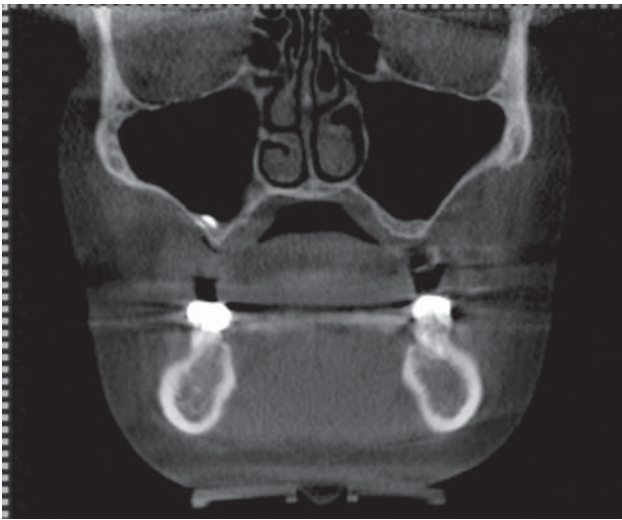*Ligija Kise*<sup>1</sup> – M.D., PhD, assoc. prof.

*Peteris Apse*<sup>2</sup> – D.D.S., MSc, Dip Prosthodontics (Toronto), Dr. Habil. Med., prof.

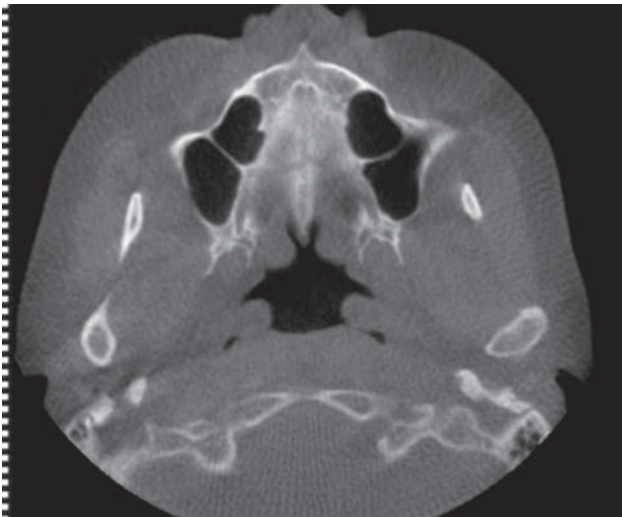
*Gints Kragis*<sup>2</sup> – M.D., D.D.S., Dip Prosthodontics, assist.

*Andris Bigestans*<sup>3</sup> – M.D., D.D.S., MRCSEd, assist.

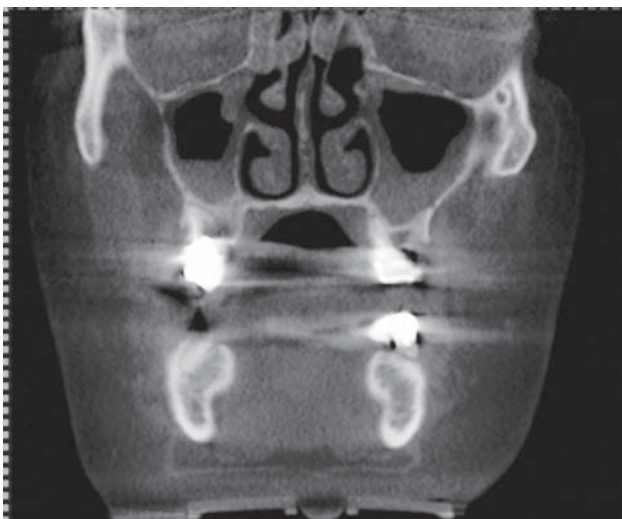Address correspondence to Ilze Dobele, Department of Otolaryngology, Riga Stradins University, Pilsõnu 13, LV-1002, Riga, Latvia. E-mail address: [Ilze.Dobele@rsu.lv](mailto:Ilze.Dobele@rsu.lv)



**Fig. 1.** Pneumatized maxillary sinuses with opened ostium, coronal view

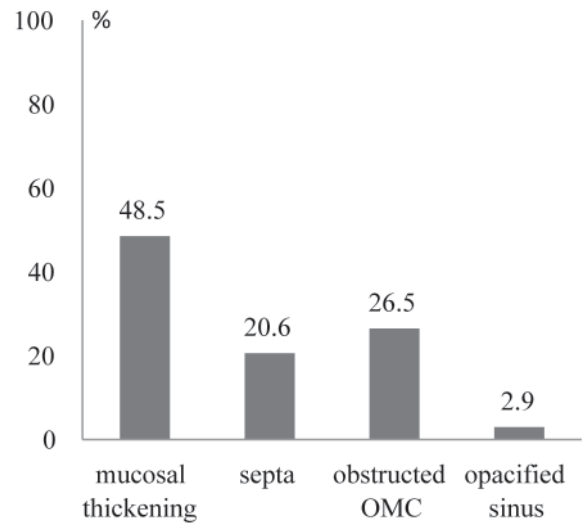


**Fig. 3.** Septa in both maxillary sinuses, axial view

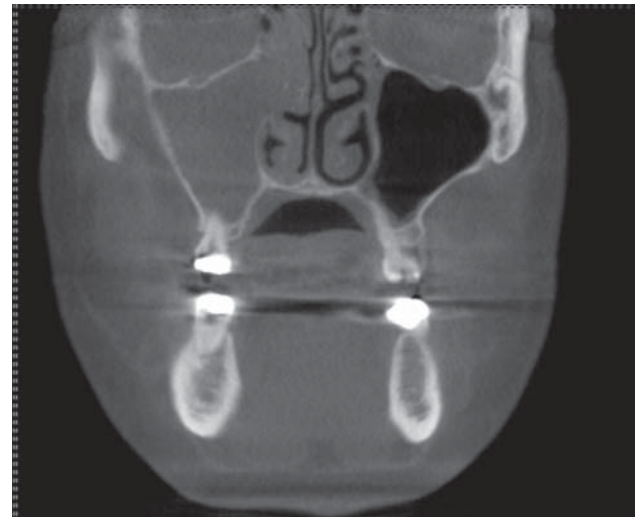


**Fig. 5.** Mucosal thickening and blocked ostium in both maxillary sinuses, coronal view

the risk of the planned procedure (5- 7). Viral or bacterial infection, edema as a result of an allergic reaction, trauma, and tumor can cause obstruction of



**Fig. 2.** Graphical representation of findings in maxillary sinuses



**Fig. 4.** Total opacification in the right maxillary sinus, coronal view

the maxillary sinus (8, 9). Reaction to dental treatment, sinus floor elevation and periodontal disease may cause the mucosal thickening in the floor of the maxillary sinus (10, 11). Perforation of the sinus membrane during sinus floor elevation is the most common complication, with the incidence rate of approximately 30% (12, 13). Anatomic variations within the sinus, such as septa, mucosal thickening of the sinus floor increase the risk of the sinus membrane perforation during pre- implant surgery in posterior maxilla (14). Computed tomography images allow the location of anatomic structures and provide information about bone dimensions and morphology (15-18). CBCT can accurately capture, display and provide 3-dimensional visualization of maxillofacial anatomy and pathology. In maxillary sinus floor elevation procedure, it is important to be acquainted with different anatomic and pathologic findings in sinus, to minimize the risk of postoperative complications.

## MATERIALS AND METHODS

In this retrospective study, 34 patients attending a private dental clinic and who were planned for pre-implant surgery were referred for CBCT examination of the maxillofacial region. The examinations were performed using I-CAT cone beam computed tomography (Imaging Sciences International, Hatfield, PA, USA). The tomography specifications were: tube potential (kV) 120, tube current (mA) 5, reconstruction time (s) <30, Voxel size (mm) 0.25-0.4, scan time (s) 8-9. Image analysis was performed on the KaVo 3D eXam Vision (KaVo Dental GmbH) software, on a multiplanar reconstruction window in which the axial, coronal, and sagittal planes could be visualized in 0.2 mm intervals. CBCT datasets of patients were selected to include only those patients where the dataset showed a complete maxillary sinus, including the osteomeatal complex and entire maxillary floor (Fig. 1). CBCT scans of 34 patients (68 maxillary sinuses) were evaluated to assess the prevalence of maxillary sinus mucosal thickening and opacity, patency of sinus ostium and presence of septa. The axial images were used for identification of presence of septa. In the coronal images the presence of the mucosal thickening on the maxillary sinus floor and patency of sinus ostium were evaluated. The mucosa could be visualized only at a minimum thickness of 2 mm or more, and therefore historically >2 mm was considered a reliable threshold for pathological mucosal swelling (19). All measurements of mucosa were made perpendicularly to the underlying bone and the thickest area was recorded. The findings of osteomeatal complex were scored as "open" if no mucosal thickening was visible or "obturated" if it was filled with mucosa or had anatomic blockage. At the time of the retrospective data analysis, the preprosthetic therapy planning, and in most cases the pre-implant surgery had already been completed.

### Statistical analysis

Commercially available statistical software was used to analyze the data. The descriptive analysis was presented as frequency, mean  $\pm$  standard deviation (SD), 95% confidence intervals (CI) and range.

## RESULTS

The study population consisted of 34 partially edentulous patients (16 females, 18 males) average age of  $52.53 \pm 9.15$  (range 31 to 64 years). The distributions of findings in maxillary sinuses are referred to in (Fig. 2). Maxillary sinus mucosal thickening was the most frequently detected lesion observed

in 19 patients (33 sinuses)  $CI=0.3643-0.6062$ . Fourteen patients showed mucosal thickening in both sinuses, 5 patients in one sinus. The results of the present study showed the noticeable individual variability of the thickness of maxillary sinus floor mucosa, with values ranging from 2.3 mm to 12.9 mm. The average mucosal thickness was  $6.23 \pm 3.34$  mm. The obstruction of sinus ostium was found in 11 patients (18 sinuses)  $CI=0.157-0.371$ . Ostium blockage was present bilaterally in 7 patients with 4 patients having unilateral blockage. Septa (Fig. 3) was present in 14 patients (14 sinuses)  $CI=0.108-0.303$ . The total opacification (Fig. 4) together with communication with oral cavity associated with tooth extractions was detected in 2 maxillary sinuses ( $CI=0.011-0.070$ ). Mucosal thickening was evident in all sinuses with obstructed osteomeatal complex (Fig. 5). In our study there was no correlation between findings in maxillary sinus and gender or age. A strong correlation between maxillary sinus ostium obstruction and mucosal thickening was found.

## DISCUSSION

Preoperative imaging is highly clinically relevant for the detection of maxillary sinus variations and pathology, in 3D imaging the treatment plan can be modified and the outcome of preprosthetic surgery in posterior maxilla can become more predictable. Combined with clinical examination, further management options on referral to specialist can be considered for findings not directly linked to the field of dentistry. All concerned with augmentation procedure should have sufficient knowledge of the maxillary sinus anatomy and pathology. However there is limited understanding of the significance of the Schneiderian membrane thickness variations, and there is no guidelines for assessment and classification of findings in the maxillary sinus before sinus lift surgery (20, 21). Today, virtually every partially or totally edentulous patient can be accurately assessed through radiographic and clinical diagnosis, and through interdisciplinary implant team work. The use of CBCT scans can provide identification of variations in the maxillary sinus and a potential cause of sinusitis. This technique is very effective for the study of inflammatory processes. In dental examinations its intrinsic qualities enable screening for sinusitis of odontogenic origin with precision unobtainable on CT (22). The CBCT scanner provided spatial and contrast resolution to visualization of high-contrast morphology in sinus and maxillofacial bone imaging at doses comparable or less than reported for conventional diagnostic CT (23, 24).



## CONCLUSIONS

Anatomic variations and lesions of the maxillary sinus were common findings in CBCT of the maxillofacial region in dental patients referred to pre-implant surgery. From the perspective of a dentist and maxillofacial surgeon the evaluation of the maxillary sinus in CBCT appears to be relevant, additionally proprietary software has become available that will allow clinicians to manipulate digital images on a PC. Prospective investigations would

further minimize risks and identify treatment requirements as part of interdisciplinary collaboration for the well-being of the patients. Today CBCT is an integrated diagnostic method to properly assess the risk and prognosis of treatment. It is advisable to develop clinical guidelines for a complete maxillary sinus examination so that nothing is overlooked and to improve communication and collaboration between dentists, maxillofacial surgeons and otolaryngologists in providing successful oral rehabilitation and improving quality of life in dental patients.

## REFERENCES

1. Nkenke E, Stelzle F. Clinical outcomes of sinus floor augmentation for implant placement using autogenous bone or bone substitutes: a systematic review. *Clin Oral Implants Res* 2009; (Suppl. 4):124–33.
2. Fatterpekar GM, Delman BN, Som PM. Imaging the paranasal sinuses: where we are and where we are going. *Anat Rec* 2008; 291:1564–72.
3. Cagici CA, Yilmazer C, Hurcan C, Ozer C, Ozer F. Appropriate interslice gap for screening coronal paranasal sinus tomography for mucosal thickening. *Eur Arch Otorhinolaryngol* 2009;266:519–25.
4. Chan HL, Wang HL. Sinus pathology and anatomy in relation to complications in lateral window sinus augmentation. *Implant Dent* 2011;20:1–7.
5. Pignataro L, Mantovano M, Torretta S, Felisati G, Sambataro G. ENT assessment in the integrated management of candidate for (maxillary) sinus lift. *Acta Otorhinolaryngol Ital* 2008; 28:110–9.
6. Torretta S, Mantovani M, Testori T, Cappadona M, Pignataro L. Importance of ENT assessment in stratifying candidates for sinus floor elevation: a prospective clinical study. *Clin Oral Implants Res* 2013;(Suppl. A 100):57–62.
7. Carmelli G, Artzi Z, Kozlovsky A, Segev Y, Landsberg R. Antral computerized tomography pre-operative evaluation: relationship between mucosal thickening and maxillary sinus function. *Clin Oral Impl Res* 2011;22:78–82.
8. Brook I. Sinusitis of odontogenic origin. *Otolaryngol Head Neck Surg* 2006; 35:349–55.
9. Manor Y, Mardinger O, Bietlitum I, Nashef A, Nissan J, Chaushu G, et al. Late signs and symptoms of maxillary sinusitis after sinus augmentation. *Oral Surg Oral Med Oral Pathol Oral Radiol Endod* 2010;110:e1–e4.
10. Phothikhun S, Suphanantachai S, Chuenchompoonut V, Nisapakultorn K. Cone beam computed tomographic evidence of the association between periodontal bone loss and mucosal thickening of the maxillary sinus. *J Periodontol* 2012; 83:557–64.
11. Shanbhag S, Karnik P. Association between periapical lesions and mucosal thickening: a retrospective Cone-beam computed study. *J Endod* 2013;39:853–57.
12. Cakur B, Sumbullu MA, Durna D. Relationship among Schneiderian membrane, Underwood's septa, and the maxillary sinus inferior border. *Clin Implant Dent Relat Res* 2011;6:1–4.
13. Ritter L, Jurgen L, Neugebauer J, Scheer M, Dreiseidler T, Zinser MJ, et al. Prevalence of pathologic findings in the maxillary sinus in cone-beam computed tomography. *Oral Surg Oral Med Oral Pathol Oral Radiol Endod* 2011;111:634–40.
14. Neugebauer J, Ritter L, Mischkowski RA, Dreiseidler T, Schherer P, Ketterle M, et al. Evaluation of maxillary sinus anatomy by cone-beam CT prior to sinus floor elevation. *Int J Oral Maxillofac Implants* 2010;5:258–5.
15. Beaumont C, Zafiroopoulos G.G, Rohmann K, Tatakis DN. Prevalence of maxillary sinus disease and abnormalities in patients scheduled for sinus lift procedures. *J Periodontol* 2005;76:461–7.
16. Zijderveld SA, van den Bergh JPA, Schulten E, Bruggenkatte CM. Anatomical and surgical findings and complications in 100 consecutive maxillary sinus floor elevation procedures. American Association of Oral and Maxillofacial Surgeons. *J Oral Maxillofac Surg* 2008;66:1426–38.
17. Lana JP, Carneiro PM, Machado VdeC, de Souza PE, Manzi FR, Horta MC. Anatomic variations and lesions of the maxillary sinus detected in cone beam computed tomography for dental implants. *Clin Oral Implants Res* 2012;23:1398–1403.
18. Guerro ME, Jacobs R, Loubele, Schutyser F, Suetens P, van Steenberghe D. State of the art on cone beam CT imaging for preoperative planning of implant placement. *Clin Oral Investig* 2006;10:1–7.
19. Harris D, Buser D, Dula K, Grondahl K, Jacobs R, Lekholm U, et al. E.A.O. guidelines for the use of diagnostic imaging in implant dentistry. *Clin Oral Implants Res* 2002;3:566–70.
20. Janner SFM, Caversaccio M, Dubach P, Sendi P, Buser D, Bornstein MM. Characteristics and dimensions of the Schneiderian membrane: a radiographic analysis using cone beam computed tomography in patients referred for dental implant surgery in the posterior maxilla. *Clin Oral Implants Res* 2011;22:1446–53.
21. Schneider AC, Brager U, Sendi P, Caversaccio MD, Busre D, Bornstein MM. Characteristics and dimensions of the sinus membrane in patients referred for single-implant treatment in the posterior maxilla: a cone beam computed tomographic analysis. *Int J Oral Maxillofac Implants* 2013;28:587–96.
22. Maillet M, Bowles WR, McClanahan SL, John MT, Ahmad M. Cone-beam computed tomography evaluation of maxillary sinusitis. *J Endod* 2011;37:753–7.
23. Okano T, Harata Y, Sakaino R, Tsuchida R, Iwai K, Seki K, et al. Absorbed and effective doses from cone beam volumetric imaging for implant planning. *Dentomaxillofac Radiol* 2009;38:79–85.
24. Xu J, Reh DD, Carey JP, Mahesh M, Siewerdsen JH. Technical assessment of a cone-beam CT scanner for otolaryngology imaging: image quality, dose, and technique protocols. *Med Phys* 2012; 39:4932–42.

Received: 02 04 2012

Accepted for publishing: 23 12 2013