

# Radiologic features of temporomandibular joint osseous structures in children with juvenile idiopathic arthritis.

## Cone beam computed tomography study

Hadeel Al-Shwaikh<sup>1</sup>, Ilga Urtane<sup>1</sup>, Pertti Pirttiniemi<sup>2</sup>, Paula Pesonen<sup>2</sup>, Zane Krisjane<sup>1</sup>, Iveta Jankovska<sup>1</sup>, Zane Davidsons<sup>3</sup>, Valda Stanevica<sup>3</sup>

### SUMMARY

*Introduction.* Patients with juvenile idiopathic arthritis (JIA) have a high risk of temporomandibular joint (TMJ) involvement. Lesions in the TMJ appear early in the course of this disease. Evaluating the structure of the TMJ in JIA patients using cone beam computed tomography (CBCT) provides an understanding of the typical radiologic features of morphological change in TMJs of JIA patients. This study aims to report these features as seen in CBCT and thus comparing them with the features observed in a control group within the same age group and in females and males.

*Materials and methods.* Cross-sectional observational study whereby CBCTs of 65 (130 joints) patients with a confirmed JIA diagnosis and 30 (60 joints) control group - patients without JIA upto the age of 17. Structural radiologic features of the joint's hard tissues were assessed according to the research diagnostic criteria for temporomandibular disorders as developed by Ahmad et al.

*Results.* The radiologic features of the osseous structures of the TMJ occurred asymmetrically between the right and left sides when compared in the JIA and control groups. The most prevalent feature in the JIA group is condyle surface flattening for both sides. Condyle surface erosion and osteophyte were also frequent and occurred with high statistical significance in both males and females.

*Conclusions.* TMJ destruction features observed in CBCT images were prevalent in the JIA group and occurred infrequently in the control group.

**Key words:** temporomandibular joint, juvenile idiopathic arthritis, cone beam computed tomography.

### INTRODUCTION

The temporomandibular joint (TMJ) is frequently affected (17-88%) in juvenile idiopathic arthritis (JIA) and it has a high risk for inflammation and destruction in these patients (1). The age at onset of the disease is below the age of 16 and females are more often affected than males (2). The consequence of this inflammation and subsequent destruction has a large variation in severity ranging from minor mandibular asymmetries with no clinical significance to major growth deviations of the mandible. These processes lead to disturbed mandibular function and growth (1, 3-5). The TMJ can

be affected uni or bilaterally (6) and the destruction taking place over several years causes the risk of functional problems (7, 8). TMJ arthritis is difficult to diagnose at an early stage since relatively few symptoms and clinical findings are related to this joint. Once, condylar changes are developed growth is affected but also without visible changes growth can deviate. In some patients no signs of TMJ arthritis are seen since TMJ arthritis is not necessarily associated with symptoms or clinical findings (9).

TMJ condyles are frequently affected in all subtypes of JIA. Lesions in or on the condyles appear early on in the patient's life. Regardless of how minimal the damage to the TMJ really is, the craniofacial morphology may become severely disturbed. This is why JIA patient follow-up including an assessment by an orthodontist complemented by radiographic imaging of the TMJ is necessary (3).

<sup>1</sup>Orthodontic department, Riga Stradins University, Riga, Latvia

<sup>2</sup>Orthodontic department, Oulu University, Oulu, Finland

<sup>3</sup>Rheumatology department, Paediatric Clinical University Hospital, Riga, Latvia

Address correspondence to Hadeel Al-Shwaikh, Miera Iela 61-K-1-23, Riga, Latvia, LV-1013.

E-mail address: alshwaikh.h@gmail.com

It is crucial for orthodontists to be aware of the destructive potential on condyles of children as a result of JIA. Detecting these destructive signs early on in the course of the disease both clinically and radiographically is critical. The early diagnosis of the disease and being aware of the potential outcomes of the disease on the condyles facilitates the formulation of an adequate treatment plan compensating for possible future condylar destruction, hence decreasing the impact on mandibular growth and thus facial appearance. An early diagnosis is crucial and has to be done before extensive growth abnormalities are evident (9, 10).

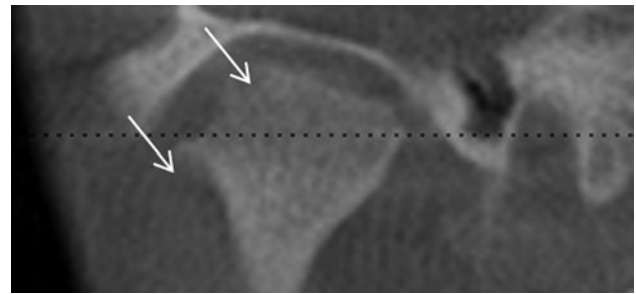
Diagnosis of TMJ arthritis always includes a clinical examination and imaging of the joint (11). The articulation surface of the condyles in JIA patients is covered by an inflamed granulation tissue (pannus), which causes destruction of the joint tissue osseous structures and causes growth disorders of the jaw as well as facial deformities (12). A normal condyle is defined as being oval and rounded in shape in the axial plane and being convex, round, or flat in the coronal plane (13). In the sagittal plane, the condyle should be round and the fossa articulare should be S shaped, with the cortical outline intact, smooth, and even in thickness (14, 15). The pathologic process can affect growth long before conventional radiographic changes are seen since these radiologic methods are unable to reveal anything more than gross osseous changes (16).

Panoramic radiology is inadequate in identifying small osseous lesions on the surface of the condyle. The advantage of using cone beam computed tomography (CBCT) is the possibility for acquiring 3D images that enable an accurate description of TMJ morphology and disorders whilst having a significantly lower radiation dose than conventional computer tomography (17, 18, 19).

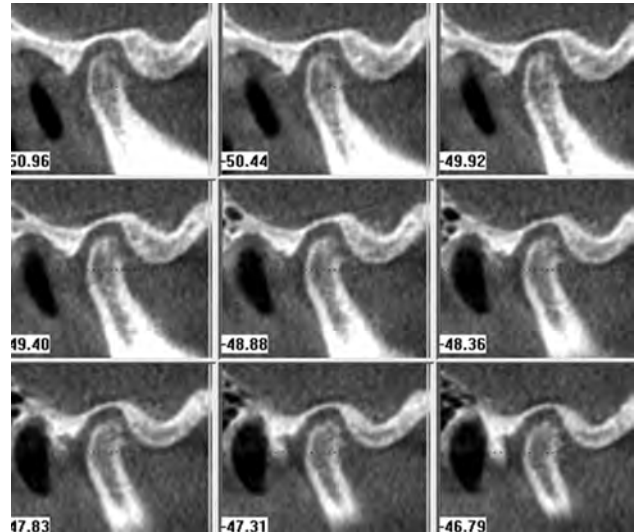
It is important to study the structure of the TMJ in JIA patients using CBCT to provide a more comprehensive understanding of the typical radiologic features of morphological change in TMJs of JIA patients. To our knowledge, as of yet, there are no investigations in the literature evaluating the CBCT images of unaffected TMJs in this age group and comparing them with JIA patients.

#### *Objectives*

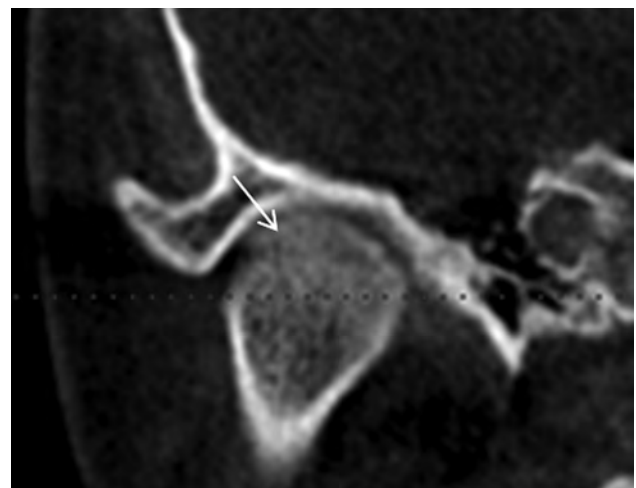
To assess the radiologic features of the osseous components of the TMJ i.e. the condyle and fossa articulare in children with JIA and compare them with patients without JIA using CBCT. To find characteristic radiological diagnostic signs and to evaluate the disorders in males and females and for both the right and left sides.



**Fig. 1.** Coronal view in CBCT slice showing erosion and osteophyte (highlighted by the arrows)



**Fig. 2.** Sagittal view of condyle with erosion, cyst, and osteophyte (highlighted by the arrows)



**Fig. 3.** Bony ankylosis seen in the coronal view of a CBCT image of a patient with JIA (highlighted by the arrows)

## MATERIALS & METHODS

This was a cross-sectional observational study in which CBCTs of 65 (130 joints) patients with a confirmed JIA diagnosis (referred from the Pediatric Clinical University hospital's Rheumatology department) and 30 (60 joints) control group - patients without JIA (obtained from the Orthodontic depart-

ment of the Stomatology Institute) were evaluated by the author with a 2-week interval to ensure reliability of assessments. All 95 patients had a clinical as well as a radiological examination.

The inclusion criteria was children upto the age of 17 and with a diagnosis of JIA with clinical TMJ symptoms and positively confirmed by MRI findings. For the control group i.e. the patients without JIA, the inclusion criteria was an age of up to 17 years as well as having an indication for a CBCT such as impacted canines or considerable facial assymetry and without presenting with TMJ symptoms. Amongst the JIA group, we had 45 females and 20 males and within the control group, 24 females and 6 males. The mean age of the JIA group was 14.2 (range 9-17), the mean age of the control group being 13.67 (range 10-17). CBCT was used for the examination and evaluation of the articular bony tissue structures and, verifying whether there was any radiographic evidence of disorders or abnormalities in the shapes of these osseous structures of the TMJ.

Structural radiologic features of the joint's osseous structures were assessed in the sagittal,

coronal and axial planes according to the research diagnostic criteria for temporomandibular disorders by computerised tomography images, as developed by Ahmad *et al.* in 2009 (20). The condyles were assessed for presence or absence of the following; hypoplasia, flattening, subcortical sclerosis, subcortical cyst (Figure 2), surface erosion (Figures 1 and 2), osteophyte (Figures 1 and 2), generalised sclerosis, loose joint body, deviation in form, and bony ankylosis (Figure 3), the fossa articulares for flattening, subcortical sclerosis and erosion, and condyle position within the fossa articulare for concentric with normal joint space, normal with decreased joint space, anterior, or posterior (see Table 1 for an accurate description of the mentioned radiologic features).

This study was carried out in the orthodontic department of Riga Stradins University's stomatology institute, the department of orthodontics at Oulu University as well as in collaboration with the pediatric clinical university hospital's rheumatology department in referring the JIA patients in order to carry out a full assessment of the TMJ and obtain a CBCT scan. The data was assessed with the super-

**Table 1.** Definition of radiologic features (20)

Feature	Definition
<b>Condyle</b>	
Hypoplasia	Normal morphology but smaller overall size
Surface flattening	Surface is no longer rounded and convex, instead taking on a flattened morphology
Subcortical sclerosis	Increased opacity and thickness in focal areas which are not present in the adjacent areas
Subcortical cyst	Hollowed out cavity below the articular surface
Surface erosion	Articular surface is no longer smooth but irregular in texture
Osteophyte	Bony projection located marginally on the condyle
Generalised sclerosis	Absence/decrease in trabeculation all through the condyle
Loose joint body	Free 'floating' calcification not connected to the condyle
Deviation in form	Alteration in morphology from the norm i.e. not convex
Bony ankylosis	Calcified ossification connecting the condyle to the temporal bone
<b>Fossa Articulare</b>	
Surface flattening	Surface is no longer rounded, instead taking on a flattened morphology
Subcortical sclerosis	Increased opacity and thickness in focal areas which are not present in the adjacent areas
Surface erosion	Articular surface is no longer smooth but irregular in texture
<b>Condyle position</b>	
Concentric with enough joint space	Centrally positioned condyle within the fossa articulare whereby the space between the articular surface of the condyle and the articular surface of the fossa is adequate
Concentric with decreased joint space	Centrally positioned condyle within the fossa articulare whereby the space between the articular surface of the condyle and the articular surface of the fossa is decreased or narrow
Anterior	Anteriorly positioned condyle within the fossa articulare i.e. when there is a longer distance from the most posterior margin of the condyle to the posterior wall of the fossa articulare
Posterior	Posteriorly positioned condyle within the fossa articulare i.e. when there is a shorter distance from the most posterior margin of the condyle to the posterior wall of the fossa articulare

vision of a radiologist as this provided an accurate evaluation of absent and or present destructive signs. Statistics and data analysis were performed in collaboration with Oulu University specialists.

For the CBCT images, the data was processed and analysed with I-CAT Vision equipment (Imaging Sciences International, Inc. Hatfield PA, USA). Equipment used standardised protocol: voltage: 120 KV, current: 38 mA, field of view: 17 cm, resolution: 0.4 voxels, radiation dose 36  $\mu$ Sv. Statistical data analysis was performed to evaluate the distribution of the radiologic osseous structural changes in the two study groups. Data was entered into MS Excel and processed by SPSS (version 20.0, SPSS Inc., Chicago, IL, USA). Intra-examiner agreement with a two week interval between each evaluation was calculated by the kappa value. Chi-squared and Fisher's exact tests were used to calculate statistical significances between the features, genders and sides (ordinal variables) of the osseous structures of the TMJ.

This study was approved by the permission of the Ethics Committee of Riga Stradins University (Decision accepted with the principles laid down in the Declaration of Helsinki).

## RESULTS

A comparison of the frequency of the TMJ osseous structures' radiologic features between the JIA and the control group related to the right and left side regardless of the gender, can be seen in Table 2. It has been found that statistical significances exist for the most prevalent features, which include, surface flattening where for the JIA group, 81.5% ( $p < 0.0001$ ) of the right condyles and 90.8% ( $p < 0.0001$ ) of the left condyles are affected, and for the control group 3.3% ( $p < 0.0001$ ) of right condyles and 6.7% ( $p < 0.0001$ ) of left condyles are affected. Surface erosion occurred in 53.8% ( $p < 0.0001$ ) of the right condyles, and 48.5% ( $p < 0.0001$ ) of the left condyles in the JIA group, and osteophyte appeared in 29.2% ( $p = 0.001$ ) of the right condyles and 27.7% ( $p = 0.001$ ) of the left condyles in the JIA group. With regards to the fossa articulare, it can be seen that surface flattening of the fossa is the only finding to have a statistical significance in both sides. Regarding the position of the condyle within the fossa, a concentrically positioned condyle with enough joint space is the most common amongst the JIA group where it occurred in 44.6% ( $p < 0.0001$ )

**Table 2.** Comparison of frequency of radiologic features of the TMJ between the JIA and the control group for the right and left sides in both genders females and males

Feature (condylar head)	JIA		Control		Right (p value)	Left (p value)
	Frequency Right side (%)	Frequency Left side (%)	Frequency Right side (%)	Frequency Left side (%)		
Hypoplasia	29.2	26.2	6.7	3.3	0.016*	0.010*
Surface flattening	81.5	90.8	3.3	6.7	<0.0001*	<0.0001*
Subcortical sclerosis	27.7	18.5	0	0	0.001*	0.016*
Subcortical cyst	16.9	18.5	0	0	0.015*	0.016*
Surface erosion	53.8	48.5	0	0	<0.0001*	<0.0001*
Osteophyte	29.2	27.7	0	0	0.001*	0.001*
Generalised sclerosis	1.5	1.5	0	0	1.000	1.000
Deviation in form	7.7	9.2	0	0	0.176	0.172
Bony ankylosis	3.1	0	0	0	1.000	-
Feature (fossa articulare)					Right (p value)	Left (p value)
Surface flattening	20.0	21.5	0	0	0.008*	0.004*
Subcortical sclerosis	13.8	6.2	0	0	0.053	0.304
Surface erosion	6.2	12.3	0	0	0.304	0.053
Feature (condyle position)					Right (p value)	Left (p value)
Concentric with enough joint space	44.6	52.3	90.0	86.7	<0.0001*	0.001*
Concentric with decreased joint space	32.3	18.5	0	0	<0.0001*	0.016*
Anterior	12.3	12.3	6.7	10	0.496	1.000
Posterior	12.3	16.9	3.3	3.3	0.264	0.096

\* With statistical significance ( $p < 0.05$ )



of the right TMJs and in 52.3% ( $p=0.001$ ) of the left TMJs as well as being the most prevalent position feature amongst the control group where it arises in 90% ( $p<0.0001$ ) of the right TMJs and in 86.7% ( $p=0.001$ ) of the left TMJs. It is therefore evident that all the aforementioned features occurred asymmetrically in both groups and in both females and males.

The prevalence of TMJ osseous components with evident radiologic features and a comparison between the JIA and control group related to gender in both the right and left sides can be found in Table 3 for females, and in Table 4 for males. When comparing the prevalence of radiologic features of the condyle between the JIA and the control group, there exist statistically significant differences with respect to many of the features between the genders. Condyle surface flattening occurs with a frequency of 87% ( $p<0.0001$ ) of the right condyles in JIA females, and in 68.4% ( $p=0.005$ ) of right condyles for JIA males. The left condyle is affected in 91.3% ( $p<0.0001$ ) of JIA females and in 89.5% ( $p<0.0001$ ) of JIA males. Statistical significances were also noted amongst the females with regards to condyle surface erosion, occurring in 58.7%

( $p<0.0001$ ) and 63% ( $p<0.0001$ ) for the right and left side respectively for JIA females, and condyle osteophyte with a 39.1% ( $p<0.0001$ ) prevalence in the right condyles and 30.4% ( $p=0.001$ ) in the left condyles in JIA females. Surface flattening of the fossa articulare is statistically significant only in females when compared between the JIA and control groups. For the position of the condyle within the fossa, statistically significant differences with regards to concentric condyles with enough joint space and concentric condyles with decreased joint space existed also in the females for both sides. Loose joint body concerning the condyle was completely absent in the females and males, and within the JIA and control group.

Amongst the control group 8.3% ( $p=0.038$ ) of right condyles and 4.2% ( $p=0.025$ ) of left condyles displayed hypoplasia and 4.2% ( $p<0.0001$ ) of right and 8.3% ( $p<0.0001$ ) of left condyles showed surface flattening, these occurred in the female patients only (Table 3). All other features were absent as expected. With regards to the position of the mandibular condyle within the fossa articulare, all condyles in the control group males and 87.5% ( $p<0.0001$ ) of right condyles and 83.3% ( $p=0.009$ )

**Table 3.** Comparison of the frequency of radiologic features of the TMJ between the JIA and control group for both the right and left side in females

Feature (condylar head) FEMALE	JIA		Control		Right (p value)	Left (p value)
	Frequency Right side (%)	Frequency Left side (%)	Frequency Right side (%)	Frequency Left side (%)		
Hypoplasia	32.6	28.3	8.3	4.2	0.038*	0.025*
Surface flattening	87.0	91.3	4.2	8.3	<0.0001*	<0.0001*
Subcortical sclerosis	28.3	23.9	0	0	0.003*	0.012*
Subcortical cyst	17.4	19.6	0	0	0.044*	0.023*
Surface erosion	58.7	63.0	0	0	<0.0001*	<0.0001*
Osteophyte	39.1	30.4	0	0	<0.0001*	0.001*
Generalised sclerosis	2.2	2.2	0	0	1.000	1.000
Deviation in form	10.9	13.0	0	0	0.157	0.087
Bony ankylosis	4.3	0	0	0	0.543	-
Feature (fossa articulare) FEMALE					Right (p value)	Left (p value)
Surface flattening	23.9	26.1	0	0	0.012*	0.006*
Subcortical sclerosis	15.2	6.5	0	0	0.087	0.546
Surface erosion	6.5	6.5	0	0	0.546	0.546
Feature (condyle position) FEMALE					Right (p value)	Left (p value)
Concentric with enough joint space	39.1	50.0	87.5	83.3	<0.0001*	0.009*
Concentric with decreased joint space	37.0	19.6	0	0	<0.0001*	0.023*
Anterior	13.0	13.0	8.3	12.5	0.706	1.000
Posterior	10.9	17.4	4.2	4.2	0.656	0.151

\* With statistical significance ( $p<0.05$ )

of left condyles in females were concentrically positioned with enough joint space, and no abnormal radiologic features were found concerning the fossa articularare.

There were no statistical significances to prove that all of the features of the osseous components of the TMJ had a predilection to the right or left side when compared between the JIA females and JIA males (Table. 5). However, osteophytes seemed to prefer the right condyle ( $p=0.007$ ) whereas surface erosion of the fossa articularare had a partiality for the left side ( $p=0.041$ ).

## DISCUSSION

This study demonstrates the most prevalent radiologic features of the osseous structures of the TMJ in JIA patients in comparison to patients without JIA by assessing the CBCT images of these patients. Our results suggest that structural differences exist between the TMJs of the JIA patients and the control group, as well as between males and females and between the left and right side. Our study does come with a few important limitations regarding the collection of the JIA sample. Our

sample consists of JIA patients who were admitted into the pediatric hospital within the last 2 years. The time elapsed between the diagnosis and the taking of the CBCT could also be a factor in the degree of severity of radiologic features observed. The next criterion is the occlusion, our study sample included Class I and Class II patients. We also did not take into account the TMJ symptoms the patient presented with such as limited mouth opening, pain on palpation and clicking or crepitation as this was not the aim of our study. In further studies, it would be interesting to evaluate whether JIA subtype, duration of disease, occlusion, and clinical symptoms are related in any way to the specific destruction features observed within the TMJ in CBCT of a JIA population. The kappa value was calculated to test the intra-examiner agreement, and came to 0.834 which indicates an almost perfect agreement. Since the examination of the TMJ in CBCT is rather subjective and viewing the condyle and fossa in different slices and thickness could alter the perception of absence or presence of certain features leading to an increased or decreased kappa value. To achieve more informative and reliable results, A larger group of patients without JIA should be used.

**Table 4.** Comparison of the frequency of radiologic features of the TMJ between the JIA and control group for both the right and left side in males

Feature (condylar head)	JIA		Control		Right (p value)	Left (p value)
	Frequency Right side (%)	Frequency Left side (%)	Frequency Right side (%)	Frequency Left side (%)		
<b>MALE</b>						
Hypoplasia	21.1	21.1	0	0	0.540	0.540
Surface flattening	68.4	89.5	0	0	0.005*	<0.0001*
Subcortical sclerosis	26.3	5.3	0	0	0.289	1.000
Subcortical cyst	15.8	15.8	0	0	0.554	0.554
Surface erosion	42.1	47.4	0	0	0.129	0.057
Osteophyte	5.3	21.1	0	0	1.000	0.540
Generalised sclerosis	0	0	0	0	-	-
Deviation in form	0	0	0	0	-	-
Bony ankylosis	0	0	0	0	1.000	-
<b>Feature (fossa articularare)</b>					<b>Right (p value)</b>	<b>Left (p value)</b>
<b>MALE</b>						
Surface flattening	10.5	10.5	0	0	1.000	1.000
Subcortical sclerosis	10.5	5.3	0	0	1.000	1.000
Surface erosion	5.3	26.3	0	0	1.000	0.289
<b>Feature (condyle position)</b>					<b>Right (p value)</b>	<b>Left (p value)</b>
<b>MALE</b>						
Concentric with enough joint space	57.9	57.9	100.0	100.0	0.129	0.129
Concentric with decreased joint space	21.1	15.8	0	0	0.540	0.554
Anterior	10.5	10.5	0	0	1.000	1.000
Posterior	15.8	15.8	0	0	0.554	0.554

\* With statistical significance ( $p<0.05$ )

**Control group**

To provide insight in to the age specificities of the TMJ it is important to examine the TMJs in CBCT images from a group of patients without JIA. A normal condyle is defined as being oval and rounded in shape in the axial plane and being convex, round, or flat in the coronal plane (13). In the sagittal plane, the condyle should be round and the fossa articulare should be S shaped, with the cortical outline intact, smooth, and even in thickness (14, 15).

The results we observed within our control group of thirty children, was that the fossas were indeed S shaped and without any deviation from the norm in morphology. However, we discovered that amongst the females 8.3% of right condyles and 4.2% of left condyles displayed hypoplasia and 4.2% of right and 8.3% of left condyles showed surface flattening. The presence of these morphological features witnessed in CBCT could be attributed to the fact that condyles and the TMJ in general, undergo continuous functional remodeling as the child is growing and until the age of 18 and beyond. Hence some supposed condylar surface flattening and some perceived condylar

surface erosions might in fact be nothing more than a normal physiological process as is documented in the literature (14). Karlo *et al.*, in 2010 suggested that the condyle in childhood changes form round to oval and until the age of 7, the condyle will have formed to 80% (21). This growth may explain the small amount of patients with these features within the control group. This highlights the importance of assessing the radiological images in all three planes vigilantly as well as noting whether the suspected destructions occurred symmetrically and hence comparing the findings with those of a group without JIA.

**JIA group**

**Structure and morphology of condyle**

The involvement of the TMJ in JIA patients is described as containing heterogeneous deformities, which may be a result of local growth disturbances, remodeling, or healed destructive processes (4, 22, 23). Our study has revealed that the most prevalent radiologic features regarding the structure and morphology of the JIA condyles were surface flattening, surface erosion, and osteophytes. These results are corroborated by existing literature.

**Table 5.** Comparison of the frequency of radiologic features of the TMJ between the sides in males and females in the JIA group

Feature (condylar head)	Female		Male		Right (p value)	Left (p value)
	Frequency Right side (%)	Frequency Left side (%)	Frequency Right side (%)	Frequency Left side (%)		
Hypoplasia	32.6	28.3	21.1	21.1	0.550	0.758
Surface flattening	87.0	91.3	68.4	89.5	0.156	1.000
Subcortical sclerosis	28.3	23.9	26.3	5.3	1.000	0.093
Subcortical cyst	17.4	19.6	15.8	15.8	1.000	1.000
Surface erosion	58.7	63.0	42.1	47.4	0.279	0.278
Osteophyte	39.1	30.4	5.3	21.1	0.007*	0.550
Generalised sclerosis	2.2	2.2	0	0	1.000	1.000
Deviation in form	10.9	13.0	0	0	0.310	0.169
Bony ankylosis	4.3	0	0	0	1.000	1.000
Feature (fossa articulare)					Right (p value)	Left (p value)
Surface flattening	23.9	26.1	10.5	10.5	0.315	0.203
Subcortical sclerosis	15.2	6.5	10.5	5.3	1.000	1.000
Surface erosion	6.5	6.5	5.3	26.3	1.000	0.041*
Feature (condyle position)					Right (p value)	Left (p value)
Concentric with enough joint space	39.1	50.0	57.9	57.9	0.183	0.597
Concentric with decreased joint space	37.0	19.6	21.1	15.8	0.256	1.000
Anterior	13.0	13.0	10.5	10.5	1.000	1.000
Posterior	10.9	17.4	15.8	15.8	0.683	1.000

\* With statistical significance (p<0.05)

Arvidsson *et al.* in 2010 described the long term radiologic findings which were assessed by a different approach in terms of the methodology in MRI and conventional computed tomography (CT) in adults with long-standing JIA. With regards to the CT findings they searched for abnormal shape or size of the TMJ condyle and fossa eminence, cortical bone defects such as superior condylar concavity, cortical defects with and without a sclerotic margin and anterior condyle position in a closed mouth position. They also found bifid condyles, hyperplasia of condyles and fossa eminences as well as subchondral cysts of the condyle. These results are explained by the fact that adult patients were studied and so we cannot accurately compare those findings of hyperplasia and bifid condyles with our population of children (4).

A study conducted in 2008 by Sidiropoulou-Chatzigianni *et al.* evaluating the presence and localisation of condylar destruction and lesions observed in orthopantomograms (OPG) of 66 children with a JIA diagnosis, and assessing whether these destructions were observed uni or bilaterally found that, 50% of the children had some form of condylar destruction, and if they were present unilaterally, they seemed to favour the right TMJ condyle which was to some degree in accordance with our results since condylar hypoplasia, subcortical sclerosis and bony ankylosis were the features which were more prevalent on the right condyle. Although, the authors did not further classify these „lesions and destructions” they simply indicated if there was a presence of any form of destruction (24). Again, the radiologic method differs from our study.

Hu *et al.*, observed condyle surface erosion on conventional CT images of JIA affected children (25) supporting our findings. One year later, Hu *et al.*, published another report using CT and they found that bony abnormalities of the TMJ in children with JIA occurred in almost two-thirds of the children and they presented with ‘variable stages’ of condyle degeneration, but did not state what kind of degeneration was observed (26). Kitai *et al.* used CT and MRI to observe the TMJ and they reported similar results (27) to Hu *et al.* In 2005, Scolozzi *et al.* performed a study using both conventional CT and MRI to lead to a diagnosis of JIA and they typically noticed multiple articular bony changes (28), which again consolidate our findings.

Huntjens *et al.* in 2008, visually inspected CBCT images of JIA patients and with the 360 degree rotation they observed a multitude of condylar destruction features ranging from minor erosions of the condyle to virtually complete deformation of the

condyle (8). In 2010, Farronato G *et al.* used CBCT to quantify the TMJ osseous destruction in JIA affected patients and discovered that a significant difference existed between the volumetric values of anatomic structures on the affected side of the TMJ when compared to the unaffected side concluding that with the advent of CBCT a more accurate visualisation of early morphologic changes in the TMJ can be attained (29).

#### **Fossa articulare:**

With regards to the results of the morphologic changes within the fossa articulare, we found the presence of surface flattening, subcortical sclerosis and surface erosion to be frequent occurrences in the JIA group. A shallow or flattened fossa was associated with an abnormal condyle in the study conducted by Argyropoulou *et al.* they also stated that an absence of the condyle’s anterior part and flattening of the articular eminence are indeed related to the involvement of the articular surfaces of the TMJ joint (30). Kitai *et al.* found that the articular eminence was severely flattened and that the depth of the fossa had been markedly reduced in their JIA sample (27). This is accordance with our findings that surface flattening of the fossa articulare was a common observation within our JIA population and any structural changes in the fossa were always linked to some form of destruction in the condyle.

#### **Condyle position**

As far as we are aware there are limited studies concerning the position of the condyle within the fossa articulare in JIA affected children observed in CBCT. Hu *et al.* observed limited joint space in their JIA group that was visualized in conventional CT images (25). In our JIA sample, concentrically positioned condyles with decreased joint space occurred with a slightly less frequency than a concentric position with enough joint space.

Abundant publications exist related to the position of the condyle in the fossa in different malocclusion groups. Our control group was made up of Class I patients and since our JIA group consisted of skeletal Class I and Class II patients we may obtain a general idea of the observed positions in these populations however, we cannot compare them accurately to our observed results for the JIA group.

Pullinger *et al.* suggested that a non-concentric condyle position within the articular fossa is a feature of a class II malocclusion and that the condyles are more anteriorly positioned in patients with Class II Division 1 malocclusion than in those with Class I (31). JIA patients are generally characterized as presenting with a class II malocclusion however, in our



study the majority of condyles were concentrically positioned with enough joint space. The reason for this is that Pullinger's study population was healthy adults without JIA. Interestingly it was concluded that the shape of the fossa articulare might be influenced by the position of the condyle.

In a recent study conducted by Arieta-Miranda it was found that only some spatial differences in condylar position inside the glenoid fossa were identified between skeletal class I, class II, and class III malocclusions. Again this study incorporated adult, JIA-free subjects (32) and so cannot be compared to our results. Blaschke and Blaschke found considerable variation in condylar positioning in normal joints (33).

Our study has shown that CBCT is an excellent tool for evaluating the type(s) of osseous destruction of the TMJ as a result of this debilitating disease, a first of its type. As we have reviewed some of the literature in our discussion, it becomes increasingly apparent that there is insufficient published data

regarding the type of the TMJ osseous destruction in children as a result of JIA by using CBCT let alone a comparison of this group of patients with a control group.

## CONCLUSIONS

CBCT images showed condylar surface flattening as the most prevalent feature of the osseous structures of the TMJ followed by surface erosion and osteophyte presence on the condylar head. In the control group, some patients exhibited mild condyle surface flattening which may be attributed to normal growth and development. Radiologic features often occurred bilaterally in both genders however, some osseous features of the TMJ occurred asymmetrically and were discriminatory between the sides; condyle osteophytes favoured the right condyle whereas fossa articulare surface erosion favoured the left fossa. Females are more prevalent in the JIA group and are also more severely affected.

## REFERENCES

1. Ringold S, Cron RQ. The temporomandibular joint in juvenile idiopathic arthritis: frequently used and frequently arthritic. *Pediatr Rheumatol Online J* 2009;7:11.
2. Ferraz AM Jr, Devito KL, Guimarães JP. Temporomandibular disorder in patients with juvenile idiopathic arthritis: clinical evaluation and correlation with the findings of cone beam computed tomography. *Oral Surg Oral Med Oral Pathol Oral Radiol* 2012;114:e51-7.
3. Billiau AD, Hu Y, Verdonck A, Carels C, Wouters C. Temporomandibular joint arthritis in juvenile idiopathic arthritis: prevalence, clinical and radiological signs, and relation to dentofacial morphology. *J Rheumatol* 2007;34:1925-33.
4. Arvidsson LZ, Smith HJ, Flatø B, Larheim TA. Temporomandibular joint findings in adults with long-standing juvenile idiopathic arthritis: CT and MR imaging assessment. *Radiology* 2010;256:191-200.
5. Fjeld M, Arvidsson L, Smith HJ, Flatø B, Ogaard B, Larheim T. Relationship between disease course in the temporomandibular joints and mandibular growth rotation in patients with juvenile idiopathic arthritis followed from childhood to adulthood. *Pediatr Rheumatol Online J* 2010;8:13.
6. Te Veldhuis EC, Te Veldhuis AH, Koudstaal MJ. Treatment management of children with juvenile idiopathic arthritis with temporomandibular joint involvement: a systematic review. *Oral Surg Oral Med Oral Pathol Oral Radiol* 2014;117:581-9.e2.
7. Sidiropoulou-Chatzigianni S, Papadopoulou MA, Kolokithas G. Dentoskeletal morphology in children with juvenile idiopathic arthritis compared with healthy children. *J Orthod* 2001;28:53-8.
8. Huntjens E, Kiss G, Wouters C, Carels C. Condylar asymmetry in children with juvenile idiopathic arthritis assessed by cone-beam computed tomography. *Eur J Orthod* 2008;30:545-51.
9. Pedersen TK, Kùseler A, Gelineck J, Herlin T. A prospective study of magnetic resonance and radiographic imaging in relation to symptoms and clinical findings of the temporomandibular joint in children with juvenile idiopathic arthritis. *J Rheumatol* 2008;35:1668-75.
10. Twilt M, Mober SM, Arends LR, ten Cate R, van Suijlekom-Smit L. Temporomandibular involvement in juvenile idiopathic arthritis. *J Rheumatol* 2004;31:1418-22.
11. Müller L, Kellenberger CJ, Cannizzaro E, Ettlin D, Schraner T, Bolt IB, et al. Early diagnosis of temporomandibular joint involvement in juvenile idiopathic arthritis: a pilot study comparing clinical examination and ultrasound to magnetic resonance imaging. *Rheumatology (Oxford)* 2009;48:680-5.
12. Pirttiniemi P, Kantomaa T, Sorsa T. Effect of decreased loading on the metabolic activity of the mandibular condylar cartilage in the rat. *Eur J Orthod* 2004;26:1-5.
13. Yale SH, Allison BD, Hauptfuehrer JD. An epidemiological assessment of mandibular condyle morphology. *Oral Surg Oral Med Oral Pathol* 1966;21:169-177.
14. Brooks SL, Westesson PL, Eriksson L, Hansson LG, Barsotti JB. Prevalence of osseous changes in the temporomandibular joint of asymptomatic persons without internal derangement. *Oral Surg Oral Med Oral Pathol* 1992;73:118-122.
15. Loubele M, Bogaerts R, Van Dijck E, Pauwels R, Vanheusden S, Suetens P, et al. Comparison between effective radiation dose of CBCT and MSCT scanners for dentomaxillofacial applications. *Eur J Radiol* 2009;71:461-8.
16. Cassidy JT. Treatment of children with juvenile rheumatoid arthritis. *N Engl J Med* 1986;314:1312-4.
17. Swennen GR, Schutyser F. Three-dimensional cephalometry: spiral multi-slice vs cone-beam computed tomography. *Am J Orthod Dentofacial Orthop* 2006;130:410-6.
18. Alexiou K, Stamatakis H, Tsiklakis K. Evaluation of the severity of temporomandibular joint osteoarthritic changes related to age using cone beam computed tomography. *Dentomaxillofac Radiol* 2009;38:141-7.
19. Garagiola U, Mercatali L, Bellintani C, Fodor A, Farronato G, Lőrincz A. Change in condylar and mandibular morphology in juvenile idiopathic arthritis: cone beam volumetric imaging. *Fogorv Sz* 2013;106:27-31.
20. Ahmad M, Hollender L, Anderson Q, Kartha K, Ohrbach R, Truelove EL, et al. Research diagnostic criteria for temporomandibular disorders (RDC/TMD): development of image analysis criteria and examiner reliability for image analysis. *Oral Surg Oral Med Oral Pathol Oral Radiol Endod* 2009;107:844-60.

21. Karlo CA, Stolzmann P, Habernig S, Müller L, Saurenmann T, Kellenberger CJ. Size, shape and age-related changes of the mandibular condyle during childhood. *Eur Radiol* 2010;20:2512-7.
22. Bache C. Mandibular growth and dental occlusion in juvenile rheumatoid arthritis. *Acta Rheumatol Scand* 1964;10:142-153.
23. Larheim TA, Haanaes HR, Dale K. Radiographic temporomandibular joint abnormality in adults with micrognathia and juvenile rheumatoid arthritis. *Acta Radiol Diagn (Stockh)* 1981;22:495-504.
24. Sidiropoulou-Chatzigianni S, Papadopoulos MA, Kolokithas G. Mandibular condyle lesions in children with juvenile idiopathic arthritis. *Cleft Palate Craniofac J* 2008;45:57-62.
25. Hu YS, Schneiderman ED. The temporomandibular joint in juvenile rheumatoid arthritis: I. Computed tomographic findings. *Pediatr Dent* 1995;17:46-53.
26. Hu YS, Schneiderman ED, Harper RP. The temporomandibular joint in juvenile rheumatoid arthritis: Part II. Relationship between computed tomographic and clinical findings. *Pediatr Dent* 1996;18:312-9.
27. Kitai N, Kreiborg S, Murakami S, Bakke M, Moller E, Darvann TA, et al. A three-dimensional method of visualizing the temporomandibular joint based on magnetic resonance imaging in a case of juvenile chronic arthritis. *Int J Paediatr Dent* 2002;12:109-15.
28. Scolozzi P, Bosson G, Jaques B. Severe isolated temporomandibular joint involvement in juvenile idiopathic arthritis. *J Oral Maxillofac Surg* 2005;63:1368-71.
29. Farronato G, Garagiola U, Carletti V, Cressoni P, Mercatali L, Farronato D. Change in condylar and mandibular morphology in juvenile idiopathic arthritis: cone beam volumetric imaging. *Minerva Stomatol* 2010;59:519-34.
30. Argyropoulou MI, Margariti PN, Karali A, Astrakas L, Alfandaki S, Kosta P, et al. Temporomandibular joint involvement in juvenile idiopathic arthritis: clinical predictors of magnetic resonance imaging signs. *Eur Radiol* 2009;19:693-700.
31. Pullinger A, Solberg W, Hollender L, Petersson A. Relationship of mandibular condylar position to dental occlusion factors in an asymptomatic population. *Am J Orthod Dentofacial Orthop* 1987;91:200-6.
32. Arieta-Miranda JM, Silva-Valencia M, Flores-Mir C, Paredes-Sampén NA, Arriola-Guillen LE. Spatial analysis of condyle position according to sagittal skeletal relationship, assessed by cone beam computed tomography. *Prog Orthod* 2013;14:36.
33. Blaschke D, Blaschke T. Normal TMJ bony relationships in centric occlusion. *J Dent Res* 1981;60:90-104.

Received: 23 07 2014

Accepted for publishing: 29 06 2016