

See discussions, stats, and author profiles for this publication at: <https://www.researchgate.net/publication/23176174>

Barx1, growth factors and apoptosis in facial tissue of children with clefts

Article in *Stomatologija* / issued by public institution "Odontologijis studija" ... [et al.] · February 2008

Source: PubMed

CITATIONS

4

READS

41

3 authors, including:



Ilze Akota

Riga Stradins University

39 PUBLICATIONS 269 CITATIONS

SEE PROFILE

Barx1, growth factors and apoptosis in facial tissue of children with clefts

Benita Krivicka-Uzkurele, Mara Pilmane, Ilze Akota

SUMMARY

Objective. Clefts of lip and palate belong to the most common birth defects worldwide. Growth factors and genes play an important role in tissue growth, differentiation and induction and upregulation of growth factors, apoptosis and matrix metalloproteinases might be involved in pathogenesis of facial clefts. The aim of this study was investigation of palate tissue in children with unilateral cleft lip palate for detection of local tissue growth factors, barx1 and apoptosis.

Materials and methods. We investigated soft and hard palate tissue from 36 children with complete unilateral cleft lip and palate from cleft area. 14 children were in age before and primary dentition, but 22 children were in mixed dentition period. We examined the localization of barx1, FGFR1, NGFR, TGF β , BMP2/4, MMP2, PGP 9,5 by immunohistochemistry. TUNEL method was performed for detection of apoptotic cells.

Results. Abundance of FGFR1 positive cells was seen almost in all cases. FGFR richly stained cells of soft and hard palate tissue. Abundance of NGFR positive cells was detected in basal epithelium, hair follicles, nerve fibers in wall of blood vessels and subepithelium, and was more often seen in children before mixed dentition. TGF β has showed intensive expression in epithelium, cartilage and bone in both dentition ages. Chondrocytes, fibroblasts and macrophages expressed MMP2 predominant before mixed dentition. Regional expression of barx1 was observed in epithelium before the mixed dentition, while during mixed dentition gene appeared in hyaline cartilage. TUNEL discovered apoptosis in both dentition ages.

Conclusions. FGFR1 and TGF β are main tissue stimulating growth factors in both dentition ages. Expression of barx1 appears in cleft lip palate affected structures mainly in mixed dentition ages. NGFR and neuropeptides-containing structures are mainly characteristic in cleft tissue before mixed dentition. Distribution of genes, GF and apoptosis seem to correlate rather with dentition age than to type of CLP.

Key words: barx1, growth factors, apoptosis, cleft lip and palate.

INTRODUCTION

Clefts of the lip and palate are among the most common birth defects worldwide. They belong to the significant congenital anomaly, requiring complex long treatment and having lifelong implications for those individuals unfortunate enough to be affected. Aetiolo-

ogy of clefts is thought to be multifactorial, with both genetic and environmental factors playing a role. At present moment actual is investigation of factors, what are lack or are too much, or what are changed in the origin of clefts, especially, growth factors, genes and neuropeptides with growth properties.

Growth factors (GF) play an important role in tissue growth, differentiation and induction. The actions of GF are very complex, with each GF having both multiple and different effects on various tissue, as well as the interactions each factor may have on each other. Upregulation of growth factors, apoptosis and matrix metalloproteinases might be involved in pathogenesis of facial clefts.

Fibroblast growth factors (FGFs) regulate cell growth and differentiation and play crucial role in the

¹Institute of Anatomy and Anthropology, Riga Stradins University, Latvia

²Institute of Stomatology, Riga Stradins University, Latvia

Benita Krivicka-Uzkurele¹ – PhD student, lecturer
Mara Pilmane¹ – Dr. med., Dr. hab. med., Corresponding member of Latvian Academy of Science, Director of Institute of Anatomy and Anthropology

Ilze Akota² – D.D.S., MSc (Oslo), Dr.Med., prof.

Address correspondence to Benita Krivicka - Uzkurele, Institute of Anatomy and Anthropology, Riga Stradins University, 9 Kronvalda boulevard, Riga, Latvia, LV-1010.
E-mail: b.krivicka@inbox.lv

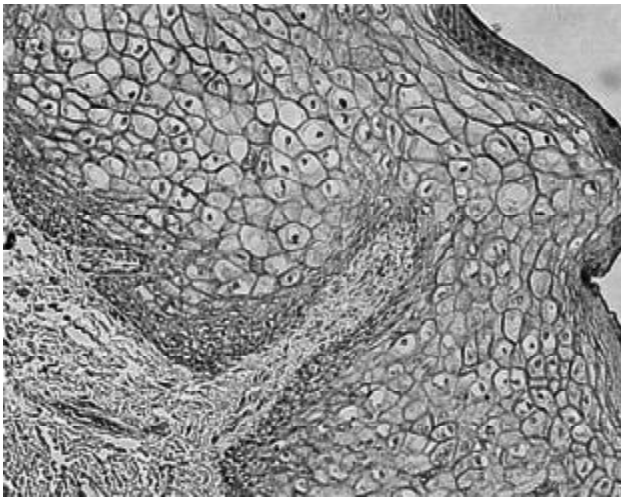


Fig. 1. FGF receptors in cytolemma of cells of epithelium (FGFR IMH, X 250)

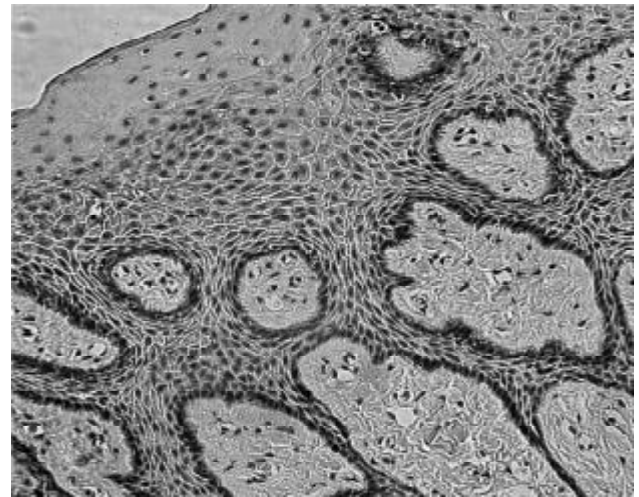


Fig. 2. NGFR-containing basal epithelial cells (NGF IMH, X 250)

process of tissue repair and remodelling. Basic FGF (bFGF) stimulates angiogenesis, fibroblast proliferation and synthesis of extracellular matrix [1]. Nerve growth factor (NGF) plays a key role in differentiation, development and survival of sympathetic and sensory nerve cells [2]. Transforming growth factors are one of the most extensively studied gene families in relation to clefting [3]. Evidence from animal studies suggests that the transforming growth factor beta (TGF β) play a central role in various aspects of secondary palate development including palate epithelial and mesenchymal differentiation [4]. Bone morphogenetic proteins (BMPs) are involved in gastrulation, mesoderm formation, left-right asymmetry, skeletal, orofacial and limb development. BMP mediates epithelial-mesenchymal interactions and induces differentiation cascade leading to bone and cartilage formation [4]. Matrix metalloproteinase 2

(MMP-2) has an important role in extracellular matrix degradation during cell migration and tissue remodeling. It is involved in development, inflammation, wound healing and other physiological and pathological processes [5]. Barx1 gene is strongly expressed in restricted areas of head and neck mesenchyme and in developing teeth [6].

MATERIAL AND METHODS

Material was obtained from 36 children with complete unilateral cleft lip and palate from cleft area during the plastical surgeries. 14 children were in age before and primary dentition, but 22 children were in mixed dentition period.

Methods:

1. Immunohistochemistry (IMH) [7]. Tissue were fixed for a day in mixture of 2% formaldehyde and

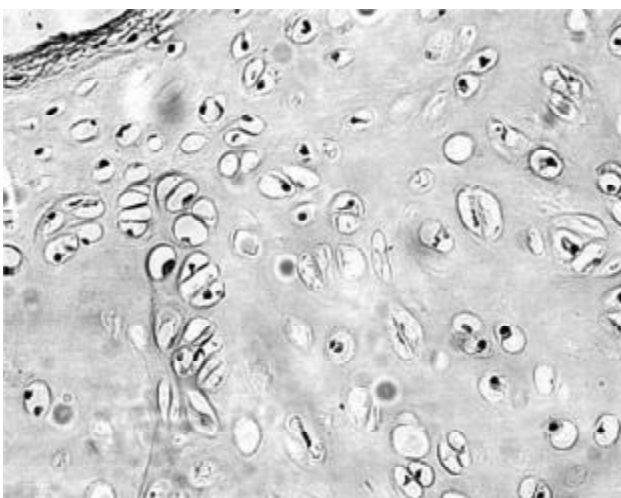


Fig. 3. Expression of TGF β in cells of cartilage (TGF β IMH, X 200)

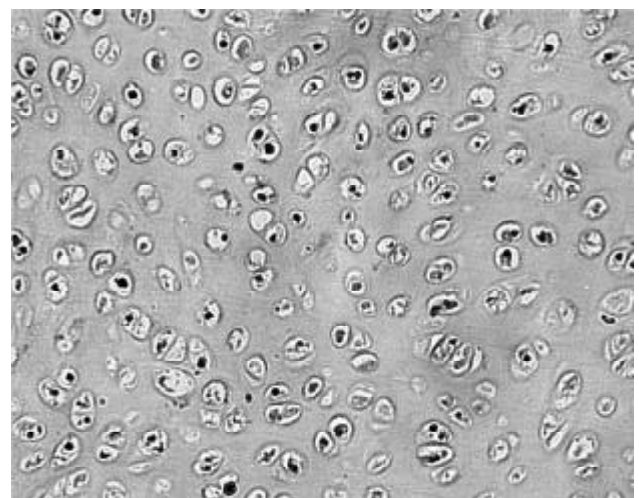


Fig. 4. Note BMP 2/4 containing chondrocytes in hyaline cartilage (BMP 2/4 IMH, X 200)

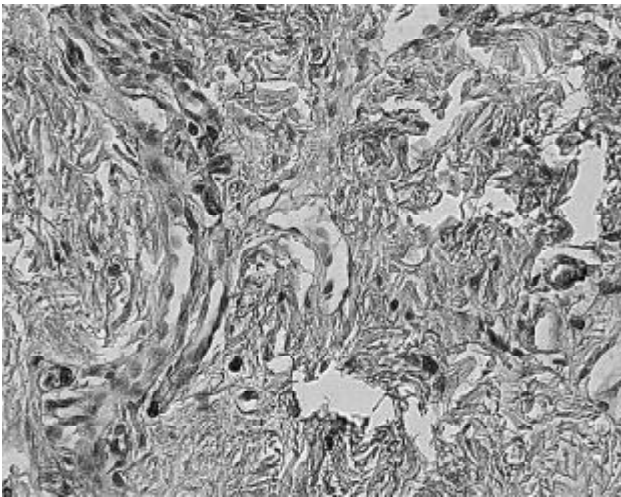


Fig. 5. MMP2 in cells of subepithelial connective tissue (MMP2 IMH, X 250)

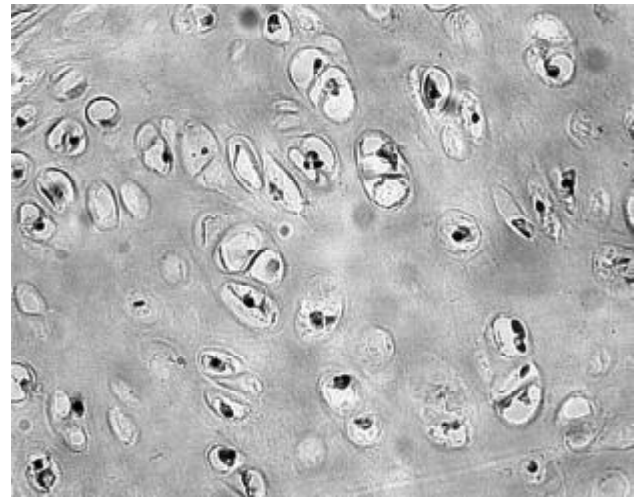


Fig. 6. Barx1 positive chondrocytes in hyaline cartilage (Barx1 IMH, X 400)

0,2% picric acid in 0,1 M phosphate buffer (pH 7,2). After samples were rinsed in thyroid buffer, containing 10% saccharose for 12 hours, then embedded into paraffin and cut in 6-7 μ m thin sections. Sections were proceeded for detection of following growth factor receptors and genes: fibroblast growth factor receptor 1 (FGFR1) (code ab 10646, work dilution 1:100, Cambridge Science Park, UK), nerve growth factor receptor (NGFR) (code M3507, work dilution 1:150, Dako, USA), transforming growth factor beta (TGF β) (code ab 1279-100, work dilution 1:100, Cambridge Science Park, UK), bone morphogenetic protein 2/4 (BMP 2/4) (code AF355, work dilution 1:100, RD Systems, UK), matrix metalloproteinase 2 (MMP2) (code AF902, work dilution 1:50, RD Systems, UK), barx1 gene (code ab26156-50, work dilution 1:250, Cambridge Science Park, UK), protein gene product 9,5 (PGP 9,5) (code Z5116, work dilution 1:200, Dako, Denmark).

2. TUNEL method was performed with In situ Cell Death Detection. POD cat No 11 684 817 910 (Roche Diagnostics, Germany) in accordance to Negoescu et al. [8].

3. Routine histological staining with haemotoksylin and eosin was developed for each case to get review picture of the slide.

RESULTS

FGFR1 presented abundance of richly stained chondrocytes, osteoblasts, fibroblasts, lymphocytes, macrophages, cells of epithelium, subaccesous gland, hair follicles, smooth muscle cells in wall of blood vessels, cytolemma of muscle fibers in all patients (Fig.1). NGFR stained basal epithelial cells, hair follicles, nerve fibers in wall of blood vessels and

subepithelium, and was more often seen in children before mixed dentition (Fig. 2). TGF α has intensive expression in epithelium, cartilage and bone in both dentition ages (Fig. 3). TGF α also was seen in moderate number in connective tissue cells in both dentition ages. BMP 2/4 richly was found in hyaline cartilage only in mixed dentition (Fig. 4). Chondrocytes, fibroblasts and macrophages expressed MMP2 predominantly before mixed dentition (Fig. 5). Regional expression of barx1 was observed in epithelium before the mixed dentition, while during mixed dentition gene appeared in hyaline cartilage (Fig. 6). PGP 9,5 showed neuropeptide-containing innervation in epithelium, around blood vessels and hair follicles, among muscle cells, and was more prominent in patients before mixed dentition.

TUNEL discovered apoptosis in both dentition ages. Few apoptotic cells to almost total apoptosis was seen in hyaline cartilage, epithelium and connective tissue cells.

DISCUSSION

Fibroblast growth factors (FGFs) play diverse roles in various tissue. FGFR1 is widespread in the epiderm, appendages, arrector pili muscle, blood vessels and dermal fibroblasts. FGF play a critical role in bone growth and development affecting both chondrogenesis and osteogenesis. FGF can act as a cell death inducer with distinct effects in proliferating and differentiating osteoblasts [9]. FGF are synthesized by osteoblasts and chondrocytes throughout the healing process [10]. Expression of FGFR1 increase in wounded skin, especially, in granulation tissues, neocapillaries and fibroblasts [11]. The prominent amount of FGFR1 in our material from clefts areas might be explained with

its necessity for tissue healing process. Our data is partially supported by study of other authors about expression of FGF in rat palatal mucosa during wound healing. Interestingly, basic fibroblast growth factor (bFGF) is detected in human saliva and actions of this growth factor are mediated by 4 different transmembrane receptors (FGFR1 to FGFR4) [12]. Thus, it might be that there is no correlation in rich expression of FGFR1 in the tissue and appearance of the same factor in patients investigated by us.

NGF we mainly observed in basal epitheliocytes. NGF is a metabolically active peptide, which was first isolated from nerve tissue. It has been widely detected as a GF for neural cells, especially sympathetic and sensory nerve cells and the cholinergic neurons of CNS. However, NGF has been also observed in cells outside the nervous system. NGF is produced by human keratinocytes, endothelial cells, skin and lung fibroblasts, chondrocytes [2]. The secretion of bioactive NGF peptides from human periodontal ligament cells and human gingival keratinocytes is also seen [13]. We suggested, that this study demonstrates significant stimulating role of NGF in cleft palate tissue repair processes.

TGF β superfamily includes many small proteins that are multifunctional (controlling growth, migration, and differentiation) during both embryonic development and postnatal tissue homeostasis [14]. TGF β play a central role in various aspects of secondary palate development including palate epithelial and mesenchymal differentiation. These processes are critical for normal palatal ontogenesis in that perturbation of either palate medial edge epithelial cell differentiation or mesenchymal cell growth results in a cleft of the palate [4]. Depending on the cell type and on other growth factors acting on the cell, TGF β may either promote or inhibit cell division in culture. TGF β induces chondrogenesis and proliferation of osteoblasts as well as apoptosis. [15, 16]. Thus, the TGF β is implicated in wound healing, possibly via their apoptosis inducing-capacity, and these functions may play a role in our patients also.

BMP 2/4 was observed in cells of hyaline cartilage. Bone morphogenetic proteins (BMPs) are multifunctional growth factors that belong to the TGF β superfamily. BMPs play important roles in heart, neural, cartilage development [17], bone formation and healing [18] and additionally regulate chondrocyte maturation [19]. Interestingly, that over-expression of BMP 4 is one of causing factor for apoptosis of oral epithelial cells in oral mucosa organ culture [20]. In our patients of mixed dentition this factor possibly influences both – growth and apoptosis of cartilage, that seems to appear more in elder children.

Prominent expression of MMP2 we found in chondrocytes and connective tissue cells.

MMP2 is involved in development, inflammation, wound healing, tumor invasion and other physiological and pathological processes. This is a key enzyme involved in matrix metabolism and cleaves several types of collagen, elastin, fibronectin, laminin [5, 21]. Matrix metalloproteinases (MMPs) is essential in normal palatogenesis, and disruption of their activity may result in cleft palate [22]. Some investigations with animals show, that during pathological conditions chondrocytes produce MMPs with following degradation of extracellular matrix [23, 24]. However, prominent secretion of above mentioned enzyme may be indicative of disorganisation in extracellular matrix and further complications of surgical treatment.

Barx1 gene belongs to the Bar subclass of the homeobox gene family. It acts indirectly to control epithelial differentiation and morphogenesis to produce both the specialized epithelium of the stomach and the specific folding patterns of dental epithelium that produce molar cusps [25]. Barx1 is expressed in the developing joint interzone and later in articular cartilage [26]. Expression of this mainly supportive tissue growth stimulating gene in palate epithelium of children before the primary dentition might be of stimulating character with already following expression in hard tissue (hyaline cartilage) due perhaps of active degradation process in the cartilage.

PGP 9,5 containing structures were observed in relatively small amount. It disagrees with Kato data about rich supply of nerve fibers in soft and hard palate tissues [27]. Possible explanation of these contrary data might be species differences and the same disorder that influences appearance and distribution of neuropeptide-containing structures in the region.

Apoptosis was widely observed in material from cleft area. Perhaps, it is arrested apoptosis, which is connected with over-abundant secretion of MMP2 or TGF β , because activated TGF β receptors elicit changes in remodeling of the extracellular matrix via MMP2 [4]. Total apoptosis in cartilage cells might be explained with remarkable secretion of BMP2/4 as it was mentioned above, and cartilage injury, which consistently also induces chondrocyte death in form of apoptosis [28].

CONCLUSIONS

1. FGFR1 and TGF β are main tissue stimulating growth factors in cleft disordered tissue of both dentition ages.
2. Expression of barx1 appears in cleft lip palate affected structures mainly in mixed dentition ages,

while NGFR and neuropeptides-containing innervation mainly characterizes cleft tissue in children before mixed dentition age.

3. Generally – distribution of genes, GF and apoptosis seem to correlate rather with dentition age than to type of CLP.

REFERENCES

- Kanda T, Funato N, Baba Y, Kuroda T. Evidence for fibroblast growth factor receptors in myofibroblasts during palatal mucoperiosteal repair. *Arch Oral Biol* 2003;48:213-21.
- Iannone F, De Bari C, Dell'Accio F, Covelli M, Patella V, Lo Bianco G, et al. Increased expression of nerve growth factor (NGF) and high affinity NGF receptor (p140 TrkA) in human osteoarthritic chondrocytes. *Rheumatology* 2002;41:1413-8.
- Jugessur A, Murray JC. Orofacial clefting: recent insights into a complex trait. *Curr Opin Genet Dev* 2005;15:270-8.
- Greene RM, Pisano MM. Perspectives on growth factors and orofacial development. *Curr Pharm Des* 2004;10:2701-17.
- Briknarova K, Grishaev A, Banyai L, Tordai H, Patthy L, Llinas M. The second type II module from human matrix metalloproteinase 2: structure, function and dynamics. *Structure* 1999;7:1235-45.
- Gould DB, Walter MA. Cloning characterization, localization, and mutational screening of the human BARX1 gene. *Genomics* 2000;68:336-43.
- Hsu S, Raine L, Fanger H. The use of antiavidin antibody and avidin-biotin peroxidase complex in immunoperoxidase techniques. *Am J Clin Pathol* 1981;75:816-21.
- Negoescu A, Guillerment C, Lorimer P, Robert C, Lantuejoul S, Brambilla E, et al. TUNEL apoptotic cell detection in archiver paraffin-embedded tissues. *Biochemica* 1998;3:36-41.
- Mansukhari A, Bellosto P, Sahni M, Basilico K. Signaling by fibroblast growth factors (FGF) and fibroblast growth factor 2 (FGFR-2)—Activating mutations blocks mineralization and induces apoptosis in osteoblasts. *J Cell Biol* 2000;149(6):1297-308.
- Bolander ME. Regulation of fracture repair by growth factors. *Proc Soc Exp Biol Med* 1992;200:165-70.
- Takenaka H, Yasuno H, Kashimoto S. Immunolocalization of fibroblast growth factor receptors in normal and wounded human skin. *Arch Dermatol Res* 2002;294:331-8.
- Oda Y, Kagami H, Ueda M. Accelerating effects of basic fibroblast growth factors on wound healing of rat palatal mucosa. *J Oral Maxillofac Surg* 2004;62:73-80.
- Kurihara H, Shinohara H, Yoshino H, Takeda K, Shiba H. Neurotrophins in cultured cells from periodontal tissues. *J Periodontol* 2003;74:76-84.
- Spears R, Svoboda KKH. Growth factors and signaling proteins in craniofacial development. *Semin Orthod* 2005;11:184-98.
- Mercola M, Stiles CC. Growth factor superfamilies and mammalian embryogenesis. *Development* 1988;102:451-60.
- Schuster N, Kriegelstein K. Mechanisms of TGF- α -mediated apoptosis. *Cell Tissue Res* 2002;307:1-14.
- Chen D, Zhao M, Mundy GR. Bone morphogenetic proteins. *Growth Factors* 2004;22:233-41.
- De Biase P, Capanna R. Bone morphogenetic proteins and growth factors: emerging role in regenerative orthopaedic surgery. *J Orthop Traumatol* 2007;8:43-48.
- Grimsrud CD, Romano PR, D'Souza M, Puzas JE, Schwarz EM, Reynoldz PR, et al. BMP signaling stimulates chondrocyte maturation and the expression of Indian hedgehog. *J Orthop Res* 2001;19:18-25.
- Kim SG, Chae CH, Cho BO, Kim HN, Kim HI, Kim IS, et al. Apoptosis of oral epithelial cells in oral lichen planus caused by upregulation of BMP-4. *J Oral Pathol Med* 2006;35:37-45.
- Kerrigan JJ, Mansell JP, Sengupta A, Brown N, Sandy JR. Palatogenesis and potential mechanisms for clefting. *J R Coll Surg Edinb* 2000;45:351-58.
- Brown NL, Yarram SJ, Mansell JP, Sandy JR. Matrix metalloproteinases have a role in palatogenesis. *J Dent Res* 2002;81:826-30.
- Arican M, Coughlan AR, Clegg PD, Carter SD. Matrix metalloproteinases 2 and 9 activity in bovine synovial fluids. *J Vet Med A Physiol Pathol Clin Med* 2000;47:449-56.
- Ijima Y, Kobayashi M, Kubota E. Role of interleukin-1 induction of matrix metalloproteinases synthesized by rat temporomandibular joint chondrocytes and disc cells. *Eur J Oral Sci* 2001;109:50-60.
- Miletich I, Buchner G, Sharpe PT. Barx1 and evolutionary changes in feeding. *J Anat* 2005;207:619-22.
- Church V, Yamaguchi K, Tsang P, Akita K, Logan C, Francis-West P. Expression and function of Bapx1 during chick limb development. *Anat Embriol* 2005;209:461-69.
- Kato J, Uddman R, Sundler F, Kurisu K. Immunohistochemical study of innervation of the boundary area of the hard and soft palate of the rat. *Acta Anat* 1998;163:92-8.
- D'Lima DD, Hashimoto S, Chen PC, Lotz MK, Colwell CW. Cartilage injury induces chondrocyte apoptosis. *J Bone Joint Surg Am* 2001;83:19-21.

Received: 24 03 2008

Accepted for publishing: 21 06 2008