

Osteopontin and Osteocalcin in Maxilla Tissue of Skeletal Class III Patients

Iveta Jankovska, Mara Pilmane, Ilga Urtane

SUMMARY

Bone extracellular matrix proteins osteopontin and osteonectin have important function during embryonic osteogenesis and are active in bone remodeling process. Knowledge about bone extracellular matrix proteins explores the mechanisms of craniofacial development and helps to understand better morphopathogenesis of severe dentofacial anomalies. Aim of the current study was to investigate an expression of osteopontin and osteocalcin in maxilla tissue in skeletal Class III patients.

The study group included 10 skeletal Class III patients to whom combined orthodontic and surgical treatment was recommended. Samples of *tuber maxillae* tissue from ten skeletal Class III malocclusion patients were collected due the orthognathic surgery procedure. The routine histological method was followed and samples were stained by hematoxyline-eosine. Tissue samples were stained according the standard immunohistochemical methods and expression of osteocalcin and osteopontin in maxilla tissue was examined. Distribution of these factors was evaluated semiquantitatively by counting the positive structures in visual field.

The trabecules of bone contained parallel located collagen fibers and irregular bone mineralization. Connective tissue proliferation in osteon channels was observed. Quantity of cells positive to osteopontin was higher than quantity of cells containing osteocalcin in all patterns extracted of maxilla tissue in patients with skeletal Class III.

In few cases osteocalcin positive cells were located near the border with soft tissue – close to osteogenic cells zone, but no osteocalcin was observed deeper in bone. The intensity of osteocalcin expression was variable, and differs individually despite the relatively regular osteopontin distribution in all patterns.

There were pronounced osteopontin, but not osteocalcin-containing cells with approximately similar intensity of protein expression in *tuber maxillae* in skeletal Class III patients.

Key words: orthognathic surgery, osteopontin, osteocalcin, immunohistochemistry.

INTRODUCTION

Craniofacial skeletal development and growth is a complex and strongly controlled process. Cran-

iofacial growth is an issue of the great importance in orthodontic scientific researches for long time-period, and several theories of craniofacial growth were postulated (remodeling theory, suture theory, the nasal septum theory, functional matrix hypothesis, servosystem theory) [1, 2, 3, 4, 5]. Knowledge about a cartilage and a bone is based on anatomical, endocrinological, and cellular studies, but importance of the specific growth and differentiation factors, extracellular matrix proteins, signaling mediators, and transcription factors in bone development were documented in latest molecular and biological studies.

Noncollagenous matrix proteins have a great importance in regulating of ossification and bone

¹Department of Orthodontics, Institute of Stomatology, Riga Stradins University, Riga, Latvia

²Institute of Anatomy and Anthropology, Riga Stradins University, Riga, Latvia

Iveta Jankovska¹ – D.D.S.

Mara Pilmane² – Dr. med., Dr. hab. med., Corresponding member of Latvian Academy of Science, Director of Institute of Anatomy and Anthropology

Ilga Urtane¹ – D.D.S., Dr. med., Professor and Head of Department of Orthodontics, Director of Institute of Stomatology

Address correspondence to Iveta Jankovska, Department of Orthodontics, Institute of Stomatology, Riga Stradins University, 20 Dzirciema Street, Riga, Latvia, LV 1007.

E-mail address: iveta.j@one.lv

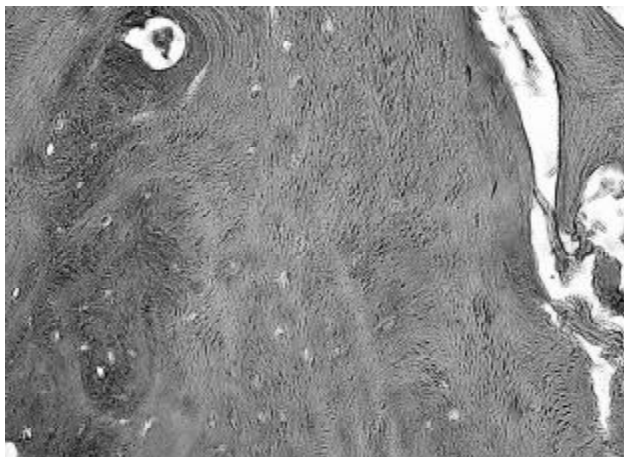


Fig. 1. Microphotograph of bone from *tuber maxillae* (haematoxylin and eosine; x250). Irregular distribution of osteone structures.

remodeling. Osteopontin is a multifunctional phosphorylated glycoprotein secreted by osteoblasts, and has been suggested to occur at an early stage during bone development and to promote attachment of osteoblasts to the extracellular matrix [6]. In normal bone tissue, osteopontin is expressed by osteoclasts and osteoblasts, and thereby is involved in bone remodeling [7]. Rodents deficient in osteopontin has an impact on wound healing, characterized by normal wound strength but abnormal maturation of collagen fibers [8]. Protein is highly expressed in bone, and also expressed by various cell types including macrophages, endothelial cells, smooth muscle cells and epithelial cells [7]. Gravallase EM [9] has investigated the role of osteopontin in connection between the immune system and bone.

Osteocalcin is a marker of bone formation, vitamin K and vitamin D dependant protein, produced by osteoblasts [10]. Although the actual function of osteocalcin is still unexplored, it may be involved in the regulation of mineralization, and its serum concentrations correlate with histomorphometric indices of newly formed bone [11, 12].

Bone extracellular matrix proteins – i.e. osteopontin and osteonectin – have important function during embryonic osteogenesis and are active in bone remodeling process. Knowledge about bone extracellular matrix proteins explores the mechanisms of craniofacial development and helps to understand better morphopathogenesis of severe dentofacial anomalies.

According to McNamara and co-authors [13] about 47% of individuals with Class III malocclusion had a retrusive position of maxilla and about 42% had some degree of mandibulae prognathism, therefore it is important to understand also the role

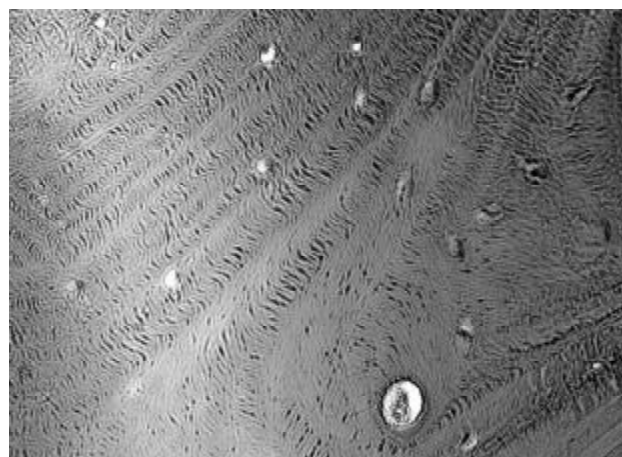


Fig. 2. Microphotograph of bone from *tuber maxillae* (haematoxylin and eosine; x 250). Chaotically organized bone structure.

of maxilla in skeletal Class III malocclusion.

Aim of the current study was to investigate an expression of osteopontin and osteocalcin in maxilla tissue in skeletal Class III patients.

MATERIALS AND METHODS

The study group included 10 skeletal Class III patients to whom combined orthodontic and surgical treatment was recommended. From them: 4 male and 6 female, at 19.4 years of age in average. Patients with skeletal asymmetries, dentofacial syndromes, cleft lip and palate were not included in the study. Orthognathic surgery in the same technique was performed by three surgeons in Riga Stradins University Institute of Stomatology, Department of Oral and Maxillofacial Surgery. Tissue samples from *tuber maxillae* were collected due the orthognathic surgery procedure as *tuber maxillae* is considered as one of the main growing centers in upper jaw. The tissue samples were fixed in 2% formaldehyde and 0.2% picric acid 0.1 M phosphate – buffer (pH 7.2). Histological investigation was performed at the Riga Stradins University Institute of Anatomy and Anthropology. Fixed tissue samples were washed in phosphate-buffered saline for 12 hours, embedded in paraffin and cut into into 6-7mm thick sections. After deparafinization osteopontin and osteocalcin expression in tissue patterns was examined by the biotin-streptavidin immunohistochemistry (IMH) [14]. The routine histological method with hematoxylineosine staining was used. Appearance of positive factors was detected semiquantitatively by counting of positive structures in visual field (0/- - occasional, + - few, ++ - moderate, +++ - numerous, ++++ - abundance positive structures in visual field

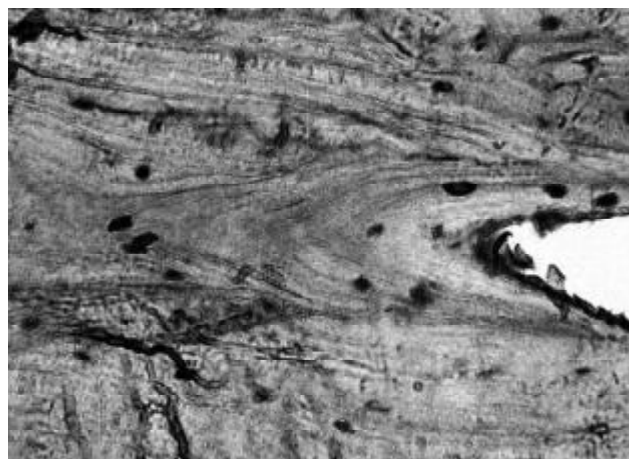


Fig. 3. Microphotograph of osteopontin expression in bone from *tuber maxillae* in Class III patient, IH, x200




Fig. 4. Microphotograph of osteopontin expression in bone from *tuber maxillae* in Class III patient, IH, x200

[15]. The study protocol for work with human originated material was approved by Ethical Committee of Riga Stradins University.

RESULTS

The trabecules of bone contained mainly parallel located collagen fibers and connective tissue proliferation in osteon channels was observed. The signs of sclerotization in soft tissue blood vessels close to bone fragments were determined (see Fig. 1, Fig. 2).

Tissue extracted from *tuber maxillae* in orthognatic Class III patients demonstrated intensively expressed, positive cells to osteopontin (++/+++; see Fig. 3, Fig. 4) and the distribution of this bone extracellular matrix protein was relatively regular. Osteopontin expressed by *tuber maxillae* osteocytes was determined in osteogenic and periosteal cells.

The expression of osteocalcin was very heterogeneous. Some specimens have no of osteocalcin positive cells (Fig. 5), and abundant in the other (Fig. 6).

Table. Expression of osteocalcin and osteopontin in bone from *tuber maxillae* in Class III patients

Number of patients	Osteocalcin	Osteopontin
1.	++++	+
2.	++++	+++
3.	0/+	+
4.	+++	+++
5.	0/+	++
6.	+ /+++	+
7.	0/+	+
8.	+++	++/++++
9.	0/+	++
10.	+++	++

In some cases osteocalcin positive cells were located near the border with soft tissue – close to osteogenic cells zone, but osteocalcin was not determined – containing osteocysts deeper in bone. The intensity of osteocalcin expression was variable, and differs individually, however distribution of osteopontin in all patterns were relatively regular (see Table). There was no difference in osteopontin and osteocalcin expression between genders.

DISCUSSION

Noncollagenous extracellular bone matrix proteins have importance in bone turnover during embryogenesis and later (and due the life-time), but their expression in matured human bone is not well defined. In present study osteopontin was the most dominant noncollagenous extracellular bone matrix protein. Osteopontin is to be an early marker of bone matrix, but osteocalcin – late marker [16]. Sasano et al. [6] suggested that bone matrix proteins continue to accumulate in the matrix as embryonic osteogenesis proceeds and bone expands its area with more intense osteopontin deposition as the periphery of bone, which consists of immature matrix components, but less intensive presence of protein in the central parts of bone that is more matured. This data corresponds to findings in current study, as osteopontin expression was relatively regular through bone with increased staining near periosteum.

Osteocalcin is produced by mature osteoblasts, odontoblasts and chondrocytes. Ducy et al. [17] in his study with the osteocalcin knockout mice reported no abnormal phenotype until 6 months of age because there was marked higher bone mass and

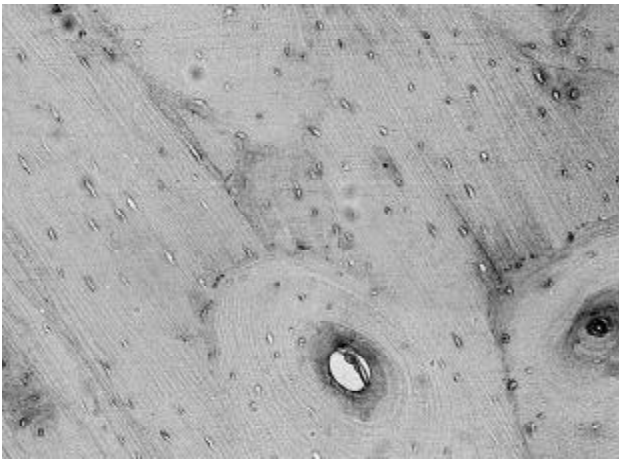


Fig. 5. Microphotograph of osteocalcin expression in bone from *tuber maxillae* in Class III patient, IH, x200

bones of improved functional quality. Another finding of Ducy et al. was the determination of the increase in osteoclast number possibly indicating the poor osteoclasts functioning in mutant mice. Findings of current study demonstrated very inconsistent expression of osteocalcin in bone from *tuber maxillae* in Class III patients, and this corresponds with clinical signs of patients, because they have excess of mandibular growth and/or normal maxillary growth, suggesting that there could be some disturbances in osteocalcin-dependent bone remodeling.

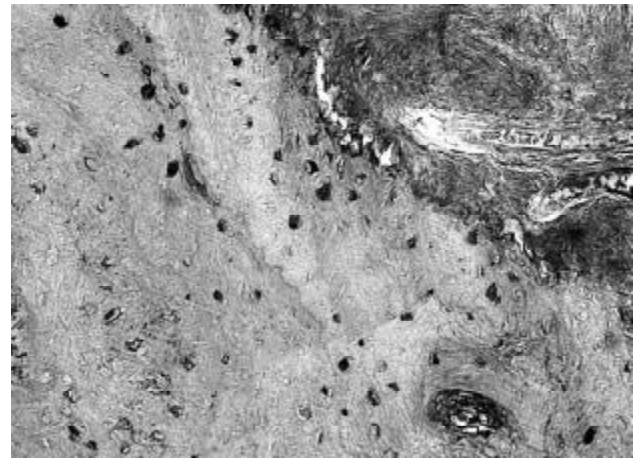


Fig. 2. Microphotograph of osteocalcin expression in bone from *tuber maxillae* in Class III patient, IH, x200

Further immunohistochemical investigation on osteocalcin and osteopontin expression helps to understand better their role in skeletal Class III growth pattern and comparison with normal craniofacial growth pattern is necessary.

CONCLUSION

Skeletal Class III patients demonstrate pronounced osteopontin, but not osteocalcin-containing cells in *tuber maxillae* with approximately similar intensity in protein expression.

REFERENCES

1. Brash JC. Some problems in the growth and development mechanics of bone. *Edinburgh Med Journal* 1934; 41(5):305-387.
2. Weinmann JP, Sicher H. Bone and bones. *Fundamentals of Bone Biology*. St Louse, CV Mosby, 1947.
3. Scott JH. The cartilage of the nasal septum: a contribution to the study of facial growth. *Br Dent J*, 1953; 95:37-43.
4. Moss ML, Young R. A functional approach to craniology. *Am J Phys Anthropol*, 1960; 18:281-292.
5. Petrovic A. Control of postnatal growth of secondary cartilages of the mandible by mechanisms regulating occlusion. *Cybernetic model*. *Trans Eur Orthod Soc* 1974; 69-75.
6. Sasano Y, Zhu JX, Kamakura S, Kusunoki S, Mizoguchi I. Expression of major bone extra cellular matrix proteins during embryonic osteogenesis in rat mandibles. *Anat Embryol* 2000; 202:31-37.
7. Mazzali M, Kipari T, Ophascharoensuk V, Wesson JA, Johnson R. Osteopontin - a molecule for all seasons. *Q J Med* 2002; 95:3-13.
8. Liaw L. Altered wound healing in mice lacking a functional osteopontin gene (*spp1*). *J Clin Invest* 1998; 101:1468-1478.
9. Gravallase EM. Osteopontin: a bridge between bone and immune system. *J Clin Invest* 2003; 112:147-149.
10. Lee AJ, Hodges S, Eastell R. Measurement of osteocalcin. *Ann Clin Biochem* 2000; 37:432-446.
11. Desbois C, Karsenty G. Osteocalcin cluster: implications for functional studies. *J Cell Biochem* 1995; 57:379-383.
12. Price PA, Williamson MK, Lothringen JW. Origin of the bone vitamin K-containing protein found in plasma and its clearance by kidney and bone. *J Biol Chem* 1981; 256:12760-12766.
13. McNamara JA, Brudon WL, *Orthodontics and Dentofacial Orthopedics*, Needham Press, Michigan, 2001, p.86.
14. Hsu S, Raine L, Fanger H. The use of antiavidin antibody and avidin-biotin peroxidase complex in immunoperoxidase techniques. *Am J Clin Pathol* 1981; 75:816-821.
15. Pilmane M, Rumba I, Sundler F, Luts A. Patterns of distribution and occurrence of neuroendocrine elements in lungs of humans with chronic lung disease. *Proc Latvian Acad Acad Sci, section B* 1998; 52:144-152.
16. Butler WT. The nature and significance of osteopontin. *Connect Tissue Res* 1989; 23:123-136.
17. Ducy P, Desbois C, Boyce B, Pinero G, Story B. Increased bone formation in osteocalcin-deficient mice. *Nature*, 1996; 382:448-452.

Received: 03 09 2009

Accepted for publishing: 28 12 2009