



Mārtiņš Kapickis

**TRANSPLANTS OF
MICROVASCULAR BUNDLES –
SOURCE OF NEOANGIOGENSIS
AND REVASCULARISATION**

Summary of promotion thesis for obtaining
a degree of a Doctor of Medicine
Speciality – Plastic Surgery

Rīga, 2012

Prk - 4/51

737796



RĪGAS STRADIŅA
UNIVERSITĀTE

Mārtiņš Kapickis

Transplants of
Microvascular Bundles –
Source of Neoangiogenesis and
Revascularisation

Summary of promotion thesis for obtaining
a degree of a Doctor of Medicine

Speciality – Plastic Surgery

Riga, 2012

0221007700

The study was carried out: at Riga Stradiņš University, at the Riga East University Hospital, at National University Hospital of Singapore and Louisville University Hospital (USA).

Scientific supervisor:

Dr. med., Professor **Guntars Pupelis**,
Riga Stradiņš University

Scientific consultant:

Dr. med., Associate Professor **Sunil Thirkannad**,
Louisville University Hospital

Official reviewers:

Dr. habil. med., Professor **Andrejs Skaģers**,
Riga Stradiņš University


Dr. med. **Jānis Ģīlis**, Plastic Surgery Clinic

Dr. med. vet., *Dr. habil. agr.* **Aleksandrs Jemeljanovs**,
Latvian University of Agriculture

The defence of the promotion thesis will be held on 18th October 2012, at 15:00 p.m., at the Specialized Surgery Council meeting of Riga Stradiņš University Hippocrate auditorium, 16 Dzirciema Str., Riga.

The promotion thesis is available at the library of Riga Stradiņš University and on the home page: www.rsu.lv

ESF National Program "Support for Implementation of Doctoral programs and Postdoctoral Research" project "Support for Implementation of Doctoral and Postdoctoral Research in Medical Sciences", according to contract Nr.2004/0005/VPD1/ESF/PIAA/04/NP/3.2.3.1./0004/0066.



Secretary of Research Council:

Dr. habil. med., Professor **Andrejs Skaģers**

CONTENTS

1. Introduction	4
1.1. Hypothesis	5
1.2. Novelty	6
1.3. Objective and tasks	7
1.4. Practice	7
1.5. Structure	7
1.6. Publications	7
2. Materials and methods	8
3. Results	15
4. Discussion	23
5. Conclusions	28
6. Practical recommendations	29
7. Original publications	30
8. Oral presentations	31
9. Annexes	32
9.1. IACUC protocol	32
9.2. Sample of pathologist of protocol	34
10. Acknowledgements	35

1. INTRODUCTION

The implantation of vascular bundles into ischemic tissue as a means of revascularization has been known for many decades. Woodhouse (1963) and Stein (1971) can be credited with some of the early work done in this field. However, even to this day, a review of literature reveals considerable confusion regarding the true clinical utility of such vascular bundle implantation. In their classical article of 1979, Hori et al. reported 100% patency and revascularization when solitary arteries were implanted into isolated living bone. They however were able to achieve only 77% patency and revascularization on implanting an entire arterio-venous bundle into necrotic bone while their success with arterio-venous fistulas was a distant 33%. Many publications that followed echoed or largely supported the results reported by Hori et al. (Figure 1.1).

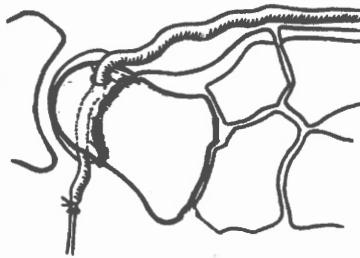


Figure 1.1. Basis of Hori's technique

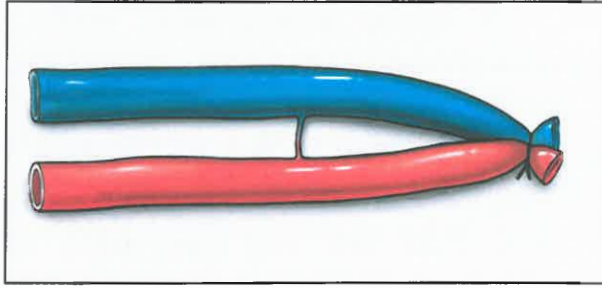
Vessel bundle has been introduced into avascular segment of bone
Source: Authors redrawing.

However, Erol and Spira reported that in their experimental series, isolated femoral arteries that were implanted into ischemic tissue underwent 100% thrombosis by 48 hours while implanted arterio-venous fistulas showed successful revascularization. This finding which seemingly contradicted that of Hori et al was partly corroborated by Tanaka et al who observed that arterio-

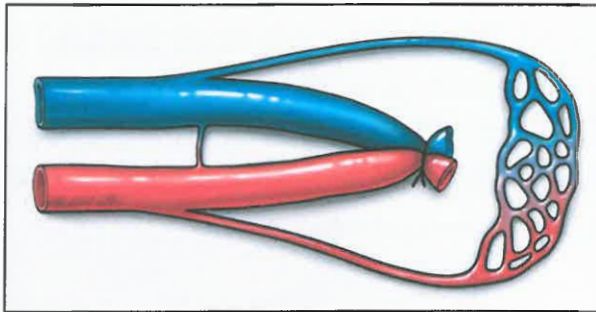
venous fistulas were superior to arterio-venous bundles as far as neovascularization was concerned. To further add to the confusion, subsequent studies began to question the very role of revascularization by neovascular sprouting from any implanted bundle. We found these seemingly contradictory reports very surprising and undertook a detailed analysis of all the above and other similar papers (Falco 1992, Nagi 2005) dealing with vascular implantation. It became evident that authors who were reporting opposing results following implantation of vascular bundles into tissues were differing in the subtleties of their experimental techniques. They were either using different vascular bundles or were preparing their vessels differently. Some of the authors even differed in the type of tissue that they implanted their vessels into (Gill 1998, Gartsman 1985). Based on these observations, we hypothesized that the varying results quoted in literature are a result of using bundles that are fundamentally different from each other.

1.1. Hypothesis

We propose that vascular bundles can be classified into two main types: (a) A “parallel pipe” type and (b) an “axial flap” type. The “parallel pipe” type means that artery and vein essentially does not communicate through either arteriovenous communication or microvascular network (Fig.1.1.A). On the other hand, the “axial flap” type of bundle has at least one of aforementioned communication (Fig.1.1.B). If ligated and implanted into a biologically neutral environment, the “parallel pipe” type of vascular bundle will thrombose while the “axial flap” type of bundle will remain patent and in addition will demonstrate neovascular sprouting.



A



B

Fig. 1.1. A - "parallel pipe" type, B - "axial flap" type

1.2. Novelty

This work is comparing two types of vascular bundles and their revascularization potential. It is commonly assumed that any dissected and ligated vessel bundle may behave as axial flap. With this experimental work it is proved that this assumption is not in accord with the reality and it explains basis of many failed revascularizations. Finding out this causal relationship is the novelty of doctoral thesis.

1.3. Objective and tasks

Objective is to clarify angiogenic potential of different ligated vascular bundles.

Tasks: (a) to determine fate of the ligated vascular bundles at different time intervals, (b) to assess reaction of the ligated vascular bundle to avascular environment, (c) to analyze reaction of different ligated vascular bundles when placed into similar (avascular) environment, (d) to determine if ligated vascular bundle can be a source of neoangiogenesis.

1.4. Practice

Angiogenic potential of ligated vascular bundles can be utilized:

- (a) in treatment of avascular necrosis of bone,
- (b) enhancement of survival of avascular adipose tissue grafts,
- (c) prefabrication of soft tissue flaps,
- (d) tissue engineering.

1.5. Structure

Doctoral Thesis has been written in Latvian and is composed of 12 sections. Volume is comprised of 101 pages including 51 figure, 6 tables and 2 annexes. 144 citations have been used.









1.6. Publications





Results of the Doctoral thesis have been published 3 times in peer reviewed journals. List of publications is attached at the end of this summary.





2. MATERIALS AND METHODS








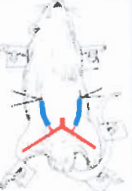
The study was conducted in accordance of approved IACUC protocol of University of Louisville Medical School. Twenty four adult Sprague –Dawley male rats weighing 250-300g were randomly selected for this study. Forty eight vessels altogether were investigated. Study protocol consisted of three major groups A, B and C (Table 2.1.).

Table 2.1.

2-6 h	A Group	Dxt. Saph	Sin. saph	Dxt. Saph	Sin. saph	Dxt saph	Sin. saph	Dxt saph	Sin. Saph	
										
		250G		255G		267G		290G		
		A-V-	A-V -	A-V-	A-V -	A-V-	A-V-	A-V -	A-V -	
		Slugging blood (mm) from ligature:								
		4	3	4	5	3	4	4	4	
										
		310G		240G		245G		255G		
		A-V-	A-V -	A-V-	A-V-	A-V-	A-V-	A-V-	A-V-	
		Slugging blood (mm) from ligature:								
4	5	5	5	5	6	4	5			

24 h				
	305G	300G	298G	245G

		Length of arterial thrombus mm.									
		3	5	3	4	5	5	4	5		
		No thrombus in the vein									
		Clinical assessment				Clinical and histological assessment					
3 weeks	B group										
		245G		256G		198G		305G			
		A+4	V-A-	A+5	V-A-	A+6	V-A-	A+4	V-A-		
		V+5		V+6		V+5		V+4			
		Assessment									
		Clin.+ histol.	Clin.	Clin.+ histol.	Clin.	Clin.+ histol.	Clin.	Clin.+ histol.	Clin.+ histol.		
		Dxt. Saph.	Sin. Epig.	Dxt. Saph.	Sin. Epig.	Dxt. Saph.	Sin. Epig.	Dxt. Saph.	Sin. Epig.		

									
		248G		256G		298G		276G	
		A+5	V-A-	A+5	V-A-	A+4	V-A-	A+4	V-A-
		V+5		V+4		A+5		A+6	
		Clinical and histological assessment							
3 weeks	C Group								
		Dxt. Epig.	Sin. Epig.	Dxt. Epig.	Sin. Epig.	Dxt. Epig.	Sin. Epig.	Dxt. Epig.	Sin. Epig.
		302G		278G		297G		288G	
		A-V-	A-V-	A-V-	A-V-	A-V-	A-V-	A-V-	A-V-
		Clinical and histological assessment							

In the Group A we determined the rate of thrombosis of atraumatically dissected and ligated bilateral saphenous vessels (that is direct continuation of femoral vessels) at 2 hours, 4 hours, 6 hours and 24 hours.

In the Group B the ligated saphenous vessels were placed in silicone sheath were examined at 3 weeks, using epigastric bundles as controls.

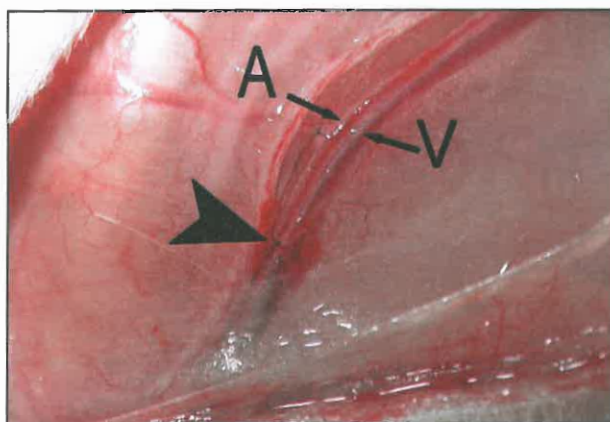
In the Group C bilaterally ligated epigastric bundles placed in silicone sheaths were examined at 3 weeks.

Animals were prepared, anaesthetized (pentobarbital) and sacrificed using methods accepted by IACUC protocol. An oblique incision was made at the groin, extending 3cm cranially. Careful dissection was done to expose 1.5 cm of the saphenous vessels and the origin of the epigastric vessels. In all

vessels ligated we used suture ligation since it is the most atraumatic method of small vessel occlusion as compared to bipolar cauterisation or hemoclip ligation.

Group A (12 rats, Bilateral saphenous vascular bundle ligation)

Under magnification (10x), the saphenous vessels were surgically ligated using 9/0 nylon sutures, 1.5cm distal to the origin of the epigastric vessels. Perivascular areolar tissues were preserved and no attempt was made to separate the saphenous artery from the vein (Fig.2.1).



2.1. att. Atraumatic ligation of a vascular bundle

No attempt to separate the artery (A) from the vein (V). Arrowhead shows the distal ligature.

The wound was closed with 3/0 silk. The procedure was repeated on the opposite side. Animals in different groups were explored at various time intervals. In the sub-group of 24-hour observation the animals were re-anesthetized.

2 rats were explored at 2 hours after ligation.

3 rats were examined at 4 hours after ligation.

3 rats were examined at 6 hours after ligation of vessels.

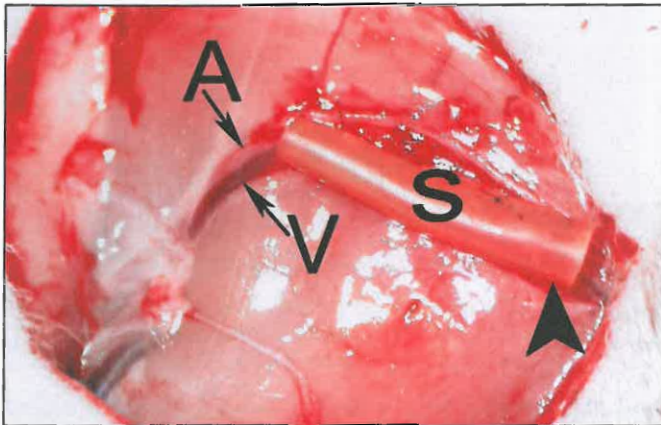4 rats were examined at 24 hrs after ligation of vessels.

The ligated vessels were laid open under the microscope and the presence of any detectable fresh thrombus was studied by observation and using saline to dissolve any red cell aggregates.

In the 24 hour group, two rats (four vessels) were evaluated using the above protocol while in the other two animals, the four ligated vascular bundles were resected and sent for histological H&E staining and evaluation for the presence of the thrombus.

Group B (5 rats, ligation of vessels and isolation in silicone sheath)

Saphenous vessels on the right were ligated and (Fig.2.2.) and rigid silicone tube with walls 1mm thick obtained from sterile urinary catheter was wrapped around the saphenous bundle and sutured in a tube-like fashion using 9/0 Ethilon sutures.



2.2.att. Silicone sheath wrapped around the saphenous bundle and sutured tightly over with 9/0 Ethilon.

A - Artery, V - Vein, Arrowhead: point of ligation inside the silicone sheet (S).

The sheet did not collapse on the vessel and allowed body fluids to bathe the ligated bundle preventing connection between the bundle and recipient bed vessels (inosculation).

This group was divided into B1 and B2 and additional procedures were performed in the same sitting.

Group B1

In 4 rats procedure was performed on the right side without ligation of the saphenous vascular bundle. This served as a control for bundle reaction to the silicone sheath. On the left bundles were ligated and wrapped with silicone as described above.

Group B2

In 4 rats the left epigastric vessel bundle was dissected out for 1.5 cm. It was ligated distally with 9/0 nylon sutures and wrapped in silicone sheet in the same way as saphenous bundle was on the right.

Animals were re-explored at 3 weeks. The silicone tube was laid open and the vessels in the silicone sheet were evaluated for flow. Segments of ligated vessels (saphenous and epigastric) were sent for H&E staining. If any thrombus was found it was measured by a micrometer. On the unligated saphenous vessel side, the silicone tube was opened and blood flow evaluated directly by observing indirect signs of patency –“uplift” test, empty-and-refill test and direct signs by cutting off the most proximal part of a vein and most distal end of an artery. Brisk bleeding from the vein and pulsatile bleeding from the artery represented patent vessels.

Group C (3 rats, ligation of epigastric vessels and isolation in silicone sheath)

Bilateral epigastric bundles were ligated dissected out for 1.5 cm; ligated distally with 9/0 nylon sutures and wrapped in silicone sheet.

Group C animals were evaluated in 3 weeks. All vessel bundles were resected and sent for histological evaluation. All histological examinations were blinded.

Statistics

24 experiment animals were included in this study. 48 vessels bundles were analyzed. Animals were distributed into 4 groups. Analyzing the results The main dependent variable is thrombosis. It is positive or negative in saphenous and/or epigastric vessels.

A group was taken as a reference group where both saphenous vessels were ligated. Thrombosis was noted not earlier than 6 hours and not later than 24 hours. Vessel bundles of A group were compared to other groups of this study.

The study data were analysed with SPSS, CIA (Confidence Interval Analysis) and Microsoft Excel software. The following descriptive and analytical statistics methods were used in the analysis: average value, maximal value, minimal value, standard deviation; Fisher's exact test was used to calculate the difference between category variables; relative risk was estimated as well. Statistical significance of the results was estimated with a confidence interval (CI) of 95% and p values. A statistically significant result is that for which a p value is less than 0.05.

3. RESULTS

Group A: Observations at 2 , 4 and 6 hours were similar. Stagnant blood was seen through the artery wall extending 4 mm proximal to the ligature. This appeared to be an erythrocyte aggregate and not true red thrombus containing fibrin since it was easily dissolved by a normal saline upon arteriotomy. There was no change in colour of the vein and when laid open - no thrombus was noted.

In 24 hour group, two animals were subjected to direct evaluation of the saphenous pedicles. In both cases both saphenous arteries where thrombosed, with fibrin clot averaging 5 mm long from the ligature site upon arteriotomy (Fig.3.1.).

Histological studies of four saphenous vessels from the remaining two animals revealed fresh, arterial, adherent thrombi with empty veins proximal to the ligature site (Fig.3.2.).

Group B (evaluated at 3 weeks), ligated saphenous arteries appeared to be thrombosed with no flow demonstrable and no tissue mass growth was noted (Fig.3.3.). Histological evaluation demonstrated organized thrombus with calcium deposits in the artery and vein, measuring from 4.6mm to 7.6 mm respectively (Fig.3.4.). There was an extensive new vessel formation on the external surface of the silicone tube.

In group B1, Silicone tube itself did not produce thrombosis of the unligated vessels on the control side. The vessels were patent and demonstrated good flow on clinical evaluation tests. Both artery and vein were bleeding when cut. On the opposite site saphenous arteries of both animals were thrombosed. Histological evaluation demonstrated organized thrombus.

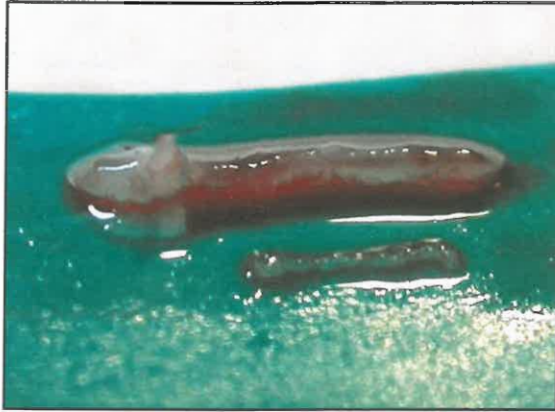


Fig. 3.1. Resected segment of a. saphena. A group, 24 hours.
Thrombectomy performed. Thrombus is in front of the artery.

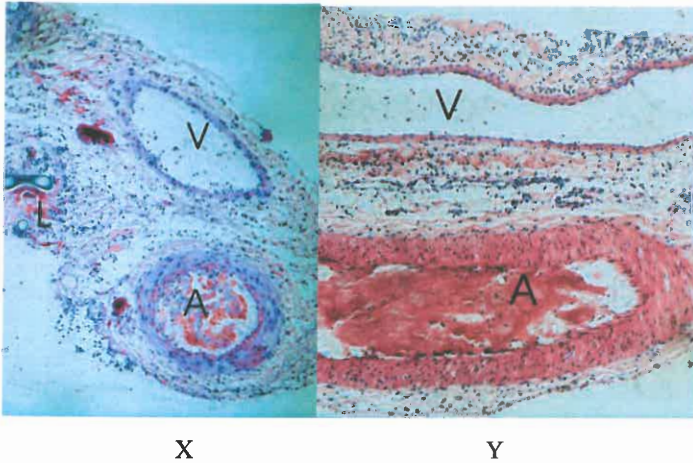


Fig. 3.2. A group, 24 hr, HE stain.

X – longitudinal cut, Y – transverse cut, 400X.

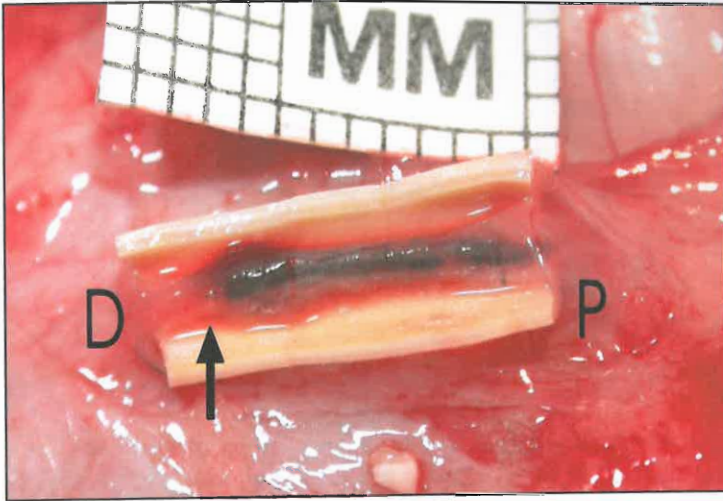
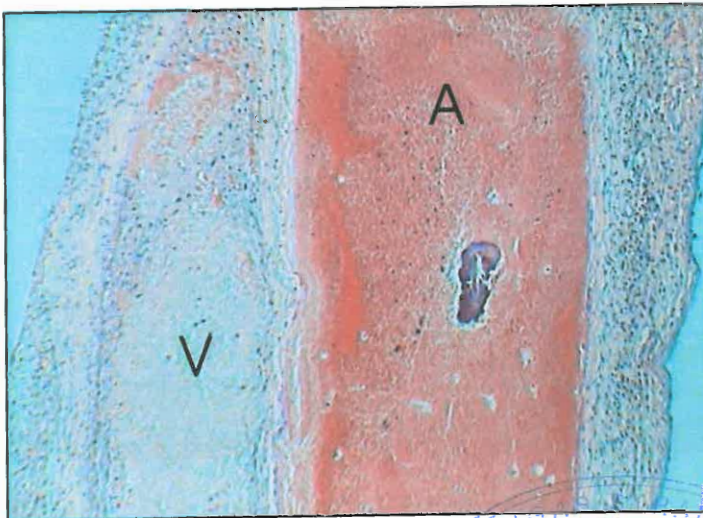


Fig. 3.3. Group B. 3 weeks. A. saphena thrombosed.

Millimeter grid gives clue about dimensions.
 Dark arrow – ligation site, P-proximal, D-distal.



**3.4.att. Group B. 3 weeks. HE stain.
 Longitudinal cut. 400 X.**

Vein – V, Artery – A with organized thrombus and Ca deposits.



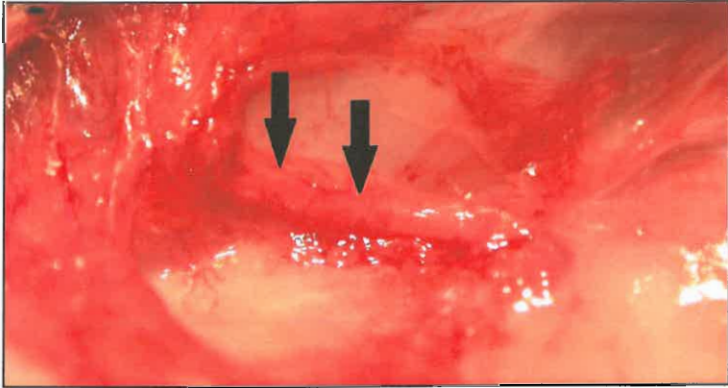


Fig. 3.5. Subgroup B2
Bundle of a. epigastrica after removal of silicone sheet. 10X
Dark arrows point to the massive neovascularisation.

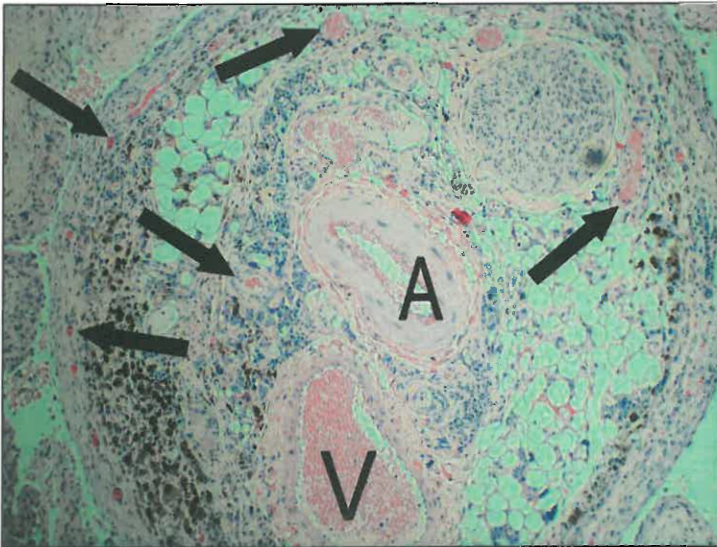


Fig. 3.6. Subgroup B2. 3 weeks.
H&E stain. Transverse section of epigastric artery in three weeks.
No thrombus are seen in the artery (A) and vein (V). True capillary bed with arterioles and venules is present around the bundle (arrows).

In group B2 no thrombus was detected in either epigastric artery or vein. There was visual tissue mass growth (Fig.3.5.) and histological evaluation demonstrated extensive neovascularization around the pedicle (Fig.3.6.).

On the opposite site saphenous arteries of all three animals were thrombosed. Histological evaluation demonstrated organized thrombus.

In group C all epigastric bundles were patent and there was visual tissue mass growth and histological evaluation demonstrated extensive capillary proliferation (neo-angiogenesis) around the pedicle.

Statistical analysis of the results

The average weight of animals (rats) included in this study was 271.1 g (95% CI; 259.1-283.2); there was no statistically significant average animal weight difference between the groups. The statistically significant difference between the groups was found in the analysis of the average blood clot length in the right artery. After performance of the Fisher's test, a statistically significant difference of the average blood clot length was found between groups A and B1 (F=4.8; p=0.05), difference = 3.5 mm (95% CI -1.3; -5.6); more significant difference was observed between groups A and B2 (F=8.3; p=0.01), difference = 3.3 (95% CI -1.1; -5.4) (Table 4.1).

Table 4.1.

A general profile of animals included in the study

Variable	Value	Group				Total
		A	B1	B2	C	
Weight (g)	Average value	271.7	251.0	269.5	291.25	271.1
	95% CI	(254.7-288.7)	(181.1-320.9)	(233.9-305.1)	(233.9-305.1)	(259.1-283.2)
	SD	26.8	43.9	22.4	10.6	28.6
	Min	240	198	248	278	198
	Max	310	305	298	302	310

Table 4.1. (continue)

The length of a blood clot in the right artery (mm)	Average value	1.3	4.8	4.5	N	2.2
	95% CI	(0.03-2.5)	(3.2-6.3)	(3.6-5.4)	N	(1.2-3.1)
	SD	1.9	0.9	0.6	N	2.3
	Min	3	4	4	N	3
	Max	5	6	5	N	6
The length of a blood clot in the left artery (mm)	Average value	1.6	N	N	N	0.8
	95% CI	(0.1-3.1)	N	N	N	(0.02-1.6)
	SD	2.4	N	N	N	1.8
	Min	4	N	N	N	4
	Max	5	N	N	N	5
The length of a blood clot in a vein (mm)	Average value	N	5	5	N	1.7
	95% CI	N	(3.7-6.3)	(3.7-6.3)	N	(0.6-2.7)
	SD	N	0.8	0.8	N	2.4
	Min	N	4	4	N	4
	Max	N	6	6	N	6

95% CI – 95% confidence interval (upper and lower limit)

SD – standard deviation

Min – minimal value

Max – maximal value

N – feature was not observed

The data were analysed using the Cochran-Mantel-Haenszel method for calculation of association variables. Relative risk (RR), which is also used in different kinds of clinical trials, was calculated as the association variable in this study. Relative risk is also used in cases of small populations and rare diseases or outcomes. Relative risk shows and measures an increase or decrease

of the probability of the event occurring (in this case - thrombosis) in an exposed group in comparison to a non-exposed group.

Thrombosis was the main dependent variable in the analysis of the results. Its occurrence (or lack thereof) was established by ligating femoral or epigastric blood vessels.

Group A (first group) was used as the reference, in which ligation of both femoral blood vessels was performed; it was observed that thrombosis occurred no sooner than after 6 hours and no later than after 24 hours.

Blood vessels and thrombosis in group A animals were compared with blood vessels and possibility of thrombosis occurrence in other animal groups. The relative risk or possibility of thrombosis occurrence is 0.66 less in group A than in groups B1 and B2; however, this difference is not statistically significant, since the confidence interval of 95% included a value of "1", meaning that the risk is equal in both groups compared; Mantel-Haenszel chi square confirms that, because the p value is more than 0.05 ($\chi^2 = 0.69$; $p = 0.20$). It follows that ligation of blood vessels does not affect the possibility of thrombosis occurrence (Table 4.2).

Table 4.2.

Data on thrombosis occurrence risk

Possibility of thrombosis, risk	Value	95% CI
In the group A	33.3%	17.8%-53.4%
In the group B1	50%	21.5%-78.5%
In the group B2	50%	21.5%-78.5%
RR (A/B1 and A/B2)	0.66	0.27-1.63

Possibility of thrombosis occurrence in group A, in which both femoral vessels were ligated, was 66% less (95% CI; 27-63%) than in group B1, in which a single femoral blood vessel was ligated and both femoral blood vessels

were additionally wrapped in a silicon coating. The same thrombosis possibility ratio (as a percentage) was in group A in comparison to group B2, in which two different blood vessels were ligated – a femoral and an epigastric one.

Analysis of the possibility of thrombosis occurrence within a single group reveals that the thrombosis risk in group A, in which both femoral blood vessels were ligated, was 33% (95% CI; 17.8%-53.4%), meaning that thrombosis after ligation of femoral blood vessels occurs in 17.8-53.4% of the cases. As to group B1, in which a single femoral blood vessel was ligated, the possibility of thrombosis occurrence was 50% (95% CI; 21.5-78.5%) - the same as in group B2, in which two different blood vessels were ligated - a femoral and an epigastric one, meaning that thrombosis after ligation of femoral or epigastric blood vessel occurs in 21.5-78.5% of the cases. In group C, in which both epigastric blood vessels were ligated, no thrombosis occurred.

4. DISCUSSION

First attempts to enhance tissue blood supply were done even before the term 'prefabrication' itself was coined. In 1935 Beck and Tichy attempted to revascularize ischemic myocardium by attaching a pectoral muscle to the left ventricle. Vineberg transplanted internal mammary artery into the myocardium attempting to augment vascularity in an ischemic tissue. Erol and Spira successfully took the matter even further attempting to create a flap based on artificial arteriovenous fistula. Mian et al. used such fistulas for new tissue formation and engineering. There are many animal studies where a femoral vessel or continuation of it (saphenous vessel) was used to create a prefabricated flap or to revascularize an avascular tissue (e.g. bone). Unfortunately it is difficult to compare these studies since they all differ in some aspects of surgical methodology and animal itself. Saldana et al have used a femoral artery as a run-through carrier to revascularize avascular bone. Some investigators use femoral artery with a stump of epigastric artery (Tanaka, 2003), while other authors have included the femoral nerve (Kostakoglu, 1997) Anatomical nomenclature has been a source of confusion in describing femoral vessel anatomy in many of the above mentioned studies. Apparently many of arteries described as femoral are saphenous arteries since they are a direct continuation of the femoral artery system (Tonken, 1993).

Falco et al. transplanted continuation of femoral bundle (artery and vein) as a unit beneath the abdominal skin of a rat. This pedicle was turned around to 180 degrees before it was placed under the skin. The authors describe the preparation technique as "skeletonisation" to the level of adventitia. There was no thrombosis and pedicle demonstrated formation of a new vessels. This tissue eventually was harvested as a free flap with survival rate of approximately 75%. The authors proposed that maintenance of patency in the femoral vessels

of a rat may be attributed to the preservation of the perivascular microcirculation, i.e. the vasa vasorum.

In our study there was thrombosis of atraumatically dissected and ligated saphenous artery in all specimens at 24 hours when bundle was placed into an isolated environment (simulating avascular bone necrosis) where there was no possibility of inosculation with surrounding vessels. We did not find any new vessel formation inside the silicone sheath. The vein was empty proximal to ligature in all cases. This contrasts with Falco's model where the femoral vascular bundle was placed in well vascularised soft tissue.

Some authors have stated, that it is intrinsic "critical microcirculation" of the bundle ensures survival of the bundle (Falco, 1992).

It has been proposed by many authors, that success of vessel transplantation into avascular tissue depends on the presence of an efferent tract for blood in the artery (Nagi, 2005). From our observations we can conclude that the saphenous vascular bundle lacks the "critical microcirculation" (Fig. 1.1.A) that helps to prevent thrombosis, but depends on early inosculation between donor and recipient vessels when used in a vascular environment for flap fabrication. When inosculation is prevented using the silicone sheath, the artery undergoes thrombosis. Many studies have proven that if artery alone was transplanted to an avascular tissue it inevitably thromboses (Hori, 1979 and Erol, 1980). This also supports the hypothesis for the need for an effective efferent venous flow.

The epigastric vascular bundle shows a different behavior when ligated and isolated within a silicone sheath, there is no arterial thrombosis at 3 weeks, and there is a visible vascular mass around the bundle. Histological examination shows extensive capillary proliferation (neo-angiogenesis) around the pedicle. This is likely to be due to presence of efferent channels from the artery. It may function as true microvascular flap (Fig.1.1A) or bundle with functioning arteriovenous shunts (Fig.4.1.).




Fig. 4.1. Vessel bundle with arteriovenous communications – a critical microcirculation.

Initial gross observation and operating microscope examination of unligated pedicles also reveals the presence of a well defined adventitial layer around the epigastric vessels which is lacking in the femoral (saphenous) bundle system (Fig. 4.2. and 4.3.).

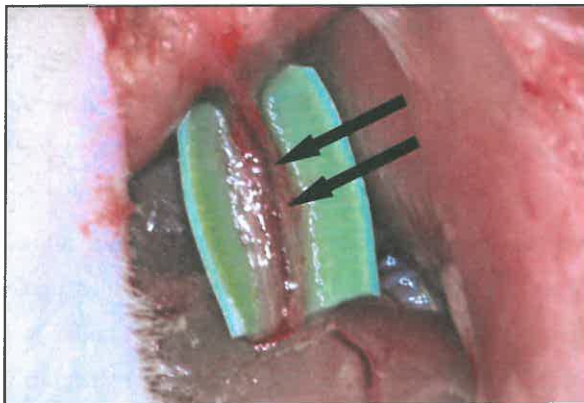


Fig. 4.2. The epigastric bundle with a rich vascularity (arrows) in the areolar tissue prior to putting a distal ligature and closing the silicone sheath.

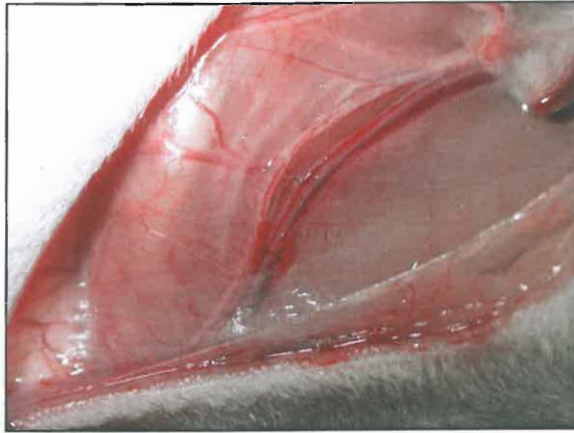


Fig. 4.3. The saphenous bundle is lacking any areolar tissue.

It must be noted that some of the specimens of epigastric bundles contain nerve tissue. This finding was inconsistent. The nerve which runs along the saphenous bundle is easy to dissect off the bundle, as opposed to the epigastric bundle where the nerve usually is not visible under direct operating microscope observation and if visible, it is impossible to dissect off the bundle without damaging it. We hypothesize that adventitial layer around the epigastric bundle contains arteriovenous drainage channels that are responsible for patency of this bundle in an isolated environment allowing vascular proliferation from the bundle itself independent of inosculation from the surrounding environment. Study by Gill et al. shows similar results. In their study revascularization of cortico-cancellous iliac crest bone graft was achieved in rats using inferior epigastric vessels. They observed bone revascularization when a flow-through pedicle was used, as well as when the pedicle was ligated distally. Authors also suggested that the patency of the ligated epigastric vascular bundle is very likely due to preservation of the soft tissue cuff around the vessels, which functions to provide adequate venous drainage. Authors

preparing saphenous bundle with inclusion of a part of epigastric, may observe a good revascularization potential for such bundles (Tanaka, 2003). It is possible that nerve running along the epigastric pedicle may be a contributing factor as in case of neurovascular flaps, but in this study we can not make such a conclusion.

5. CONCLUSIONS

A. saphena bundle does not show any signs of thrombosis at 2,4 or 6 hours, but it is thrombosed at 24 hr and remain thrombosed at least 3 weeks after ligation. A. epigastrica bundle does not thrombose and remains patent at least 3 weeks. Massive neovascularisation is observed inside the silicone sheet.

In the rat model the saphenous vascular bundle and the epigastric vascular bundles behave differently when placed in an avascular environment. The saphenous bundle is more likely to undergo thrombosis and does not produce vascular proliferation. In contrast the epigastric bundle survives in an isolated and relatively avascular environment and produces vascular proliferation. This may be attributed to the presence of effective drainage mechanism from the epigastric artery which prevents thrombosis of the ligated segment.

Gross observation under operating microscope also suggests presence of a well defined adventitial layer around the epigastric bundle which may contain the arteriovenous capillary network. This layer is lacking around the saphenous bundle.

We also hypothesise that there may be similar differences in different vascular units in the human body. Some of these pedicles may not be suitable for applications such as revascularisation of avascular bones. This requires further investigation.

6. PRACTICAL RECOMMENDATIONS

1) Harvesting vascularised bone grafts, pay attention not to skeletonize pedicle containing vascular bundle. It is important to harvest such transplants together with a supporting fascial strip thereby preserving areolar tissue and providing adequate efferent blood flow for survival and healing of transplant.

2) It is of paramount importance to preserve areolar tissue around the bundle when transplanting ligated vessel bundles for revascularization of avascular tissue. It is necessary to provide adequate length of the bundle on the opposite side of the avascular bone when transplanting through it as in Hori technique, because distal tip is most frequently subject to thrombosis. In Doctoral thesis length of blood clot in the saphenous artery was from 4.6mm till 7.6mm. Therefore we recommend transplanting bundle in such a way so that distal tip of it projects outside of the avascular segment at least 7.6 mm.

3) For revascularization of avascular tissue we suggest using bundles with “axial flap” type circulation. The only instance when we suggest using “parallel pipe” type is where it is in very close proximity to vascular axis and it is transposed without ligation.

7. ORIGINAL PUBLICATIONS

1. Kapickis M., Lim A., Lahiri A., Different angiogenic behaviour of ligated saphenous and epigastric vascular bundles in avascular environment: an in-vivo experimental study // Journal of Hand Surgery (Asian), 2010; 15(1): 17-25.
2. Kapickis M., Sassu P., Thirkannad SM. Evaluation of Two types of vascular bundles for revascularization of avascular tissue // Journal of Hand Surgery (Am), J Hand Surg Am, 2009; 34(8): 1461-1466.
3. Kapickis M., Pupelis G. Failed revascularization of the avascular tissue as a result of the thrombosis of the transplanted vascular bundle // Rīgas Stradiņa universitātes Zinātniskie raksti/ RSU Scientific papers, 2008; 23-30.

8. ORAL PRESENTATIONS

1. Kapickis M., Pupelis G., Lim A., Lahiri A. 23rd Scandinavian Hand Society Meeting, Gotland, Sweden. May 26, 2010. *Different angiogenic behaviour of ligated saphenous and epigastric vascular bundles in avascular environment: an in-vivo experimental study.*
2. Kapickis M., Pupelis G., Thirkannad MS., Lim A. 1st Baltic Hand Surgery Meeting. Riga, Latvia. May 24, 2010. *Evaluation of Two Types of Vascular Bundles for Revascularization of avascular Tissue.*
3. Kapickis M., Sunil TM., Sassu P. ASSH 62nd Annual Meeting in Seattle, WA on September 26 – 29, 2007. *Vascular bundles for revascularization of tissues. Are they all the same?*
4. Kapickis M., Sunil TM., Indiana/Louisville/Cincinnati Tri-State Hand Surgery Conference 2007. *Two types of vascular bundles for revascularization of tissues.*

9. ANNEXES

9.1. IACUC protocol

The study was conducted in accordance of approved IACUC protocol of University of Louisville Medical School on 24th of May, 2007. Complete document contains 13 pages.

Revision

FOR IACUC USE ONLY
PROPOSAL # 03033
CLASSIFICATION(S) II

UNIVERSITY OF LOUISVILLE
PROPOSAL TO USE LABORATORY ANIMALS IN RESEARCH AND TEACHING
(PLEASE TYPE)

I. ADMINISTRATION

Project Director (Individual with responsibility for the proposed study):

Name Sunil Thirkannad

University Title Assistant Clinical Professor

Department Surgery Division Hand and Microsurgery

University Address (Bldg./Room #) Kleinert Institute 225 Abraham Flexner Way Suite 250

Phone Number 562-0323E-mail sthirkannad@cmki.org ID 1520107 FAX 562-0326

Co Director(s) Martins Kapickis, MD

Project Title (limit to 60 characters including spaces)

RATE OF THROMBOSIS OF ATRAUMATICALLY LIGATED VASCULAR BUNDLES

Funding Source Kleinert Institute

Dates of Proposed Project - From: 4/15/2007 To: 1/7/2008

II. PROPOSAL TYPE (See instructions, pages i,ii, sections III,IV)

New Proposal

3-Year Renewal

Modification of Previously Approved Proposal

Provide the following information (if applicable):

Current IACUC Proposal Number (if Applicable) _____

UofL. Speedtype Number (Please include if you know) Z2004

Date of Current IACUC Approval _____

III. PROPOSAL PURPOSE

Research

Education

Professional Education

Undergraduate Education

Graduate Education

Continuing Medical Education

RECEIVED MAY 22 2007

7/1/04

IACUC Proposal Form updated 2004


IV. SIGNATURES AND APPROVALS

I certify that the statements herein are true and that if protocol changes are required, I will resubmit the proposal according to instructions given for the modification of a previously approved proposal.

As Project Director,** I will conduct the proposed research according to the principles of the "NIH Guide for the Care and Use of Laboratory Animals" and will conform to federal, state, and institutional laws or guidelines concerning the care and use of animals in research, teaching, or testing.

I understand that the IACUC has concern for the ethical aspects and implications of all studies involving animals and I will cooperate with the Committee in its consideration of these issues. I also understand that the individuals listed as project participants must comply with all IACUC training and occupational health and safety requirements.

**Project Director must be a member of the University of Louisville faculty.


Signature of Project Director _____ Date 3/29/07

DEPARTMENTAL APPROVAL: Approval implies that the Department has reviewed and endorses the proposed research, including the use of laboratory animals.


Signature of Department Chair _____ Date 3/29/07

.....
**

IACUC ACTIONS

Approved _____
Contingent Approval _____
Disapproved _____

CONTINGENCIES/REMARKS:


IACUC Chair Signature _____ Date 5/24/2007

9.2. Sample of pathologist protocol

Atraumatically ligated vascular bundles – Kapickis & Thirkannad study

Animal specimen from rat thigh

Specimen number : 3 F

Type of specimen : Epigastric – (E) / Femoral bundle – (F)

Harvested on :

Duration : 3 weeks

Impression:



Findings – YES / NO	Artery	Vein
Neovascular sprouting		
Thrombus	no	yes ✓
Adherence of thrombus	no	yes ✓
Length of thrombus (in mm)	—	
Type / organization of thrombus		Organizing Stasis thrombus
If no thrombus seen, what else was seen in the lumen		
Any other findings	caliberous - vessel wall very small vessel formation @ artery, vein, tissue bundle	

.....
Name of pathologist

.....
Signature

10. ACKNOWLEDGEMENTS

Doctoral thesis was written thanks to the ESF National Program "Support for Implementation of Doctoral programs and Postdoctoral Research" project "Support for Implementation of Doctoral and Postdoctoral Research in Medical Sciences".



I would like to acknowledge the technical help of colleagues from the Microvascular Laboratory of the National University Hospital of Singapore and University of Louisville Hospital, Department of Pathology.