

Case Report

Surgical Treatment of Hepatocellular Carcinoma with a Tumor Thrombus Invading the Right Atrium: A Case Report

Laura Veinberga^{a,b} Kristians Meidrops^{b,c} Roberts Rumba^d
Marcis Gedins^d Deniss Anufrijevs^{a,b} Janis Vilmanis^{a,b}
Karina Drizlionoka^e Edgars Zellans^e Inguna Krustina^e Juris Berzins^f
Inese Briede^{g,h} Armands Sivinsⁱ Maija Radzina^{j,f} Peteris Stradins^{b,c}
Arturs Ozolins^{a,b}

^aDepartment of Surgery, Pauls Stradins Clinical University Hospital, Riga, Latvia; ^bDepartment of Surgery, Riga Stradins University, Riga, Latvia; ^cCentre of Cardiac Surgery, Pauls Stradins Clinical University Hospital, Riga, Latvia; ^dDepartment of Vascular Surgery, Pauls Stradins Clinical University Hospital, Riga, Latvia; ^eDepartment of Cardiac Anaesthesia and Intensive Care, Pauls Stradins Clinical University Hospital, Riga, Latvia; ^fDiagnostic Radiology Institute, Pauls Stradins Clinical University Hospital, Riga, Latvia; ^gDepartment of Pathology, Riga Stradins University, Riga, Latvia; ^hPathology Institute, Pauls Stradins Clinical University Hospital, Riga, Latvia; ⁱClinic of Surgical Oncology, Riga East Clinical University Hospital, Riga, Latvia; ^jRadiology Research Laboratory, Riga Stradins University, Riga, Latvia

Keywords

Hepatocellular carcinoma · Tumor thrombus · Right atrium · Liver resection · Cavo-atrial thrombectomy

Abstract

Up to 3% of all hepatocellular carcinomas (HCCs) present with a tumor thrombus (TT) in the inferior vena cava (IVC) and right atrium (RA). Extensive growth of HCC into the IVC and the RA is associated with a particularly poor prognosis. This clinical condition is related to a high risk of sudden death due to pulmonary embolism or acute heart failure. Therefore, a technically challenging treatment undergoing hepatectomy and cavo-atrial thrombectomy is necessary. We report a 61-year-old man presenting with right subcostal pain, progressive weakness, and periodic shortness of breath for 3 months. He was diagnosed with advanced HCC with a TT extending from the right hepatic vein into the IVC and RA. A multidisciplinary meeting with cardiovascular and hepatobiliary surgeons, oncologists, cardiologists, anesthesiologists, and radiologists was held to determine the best treatment approach. Initially, the patient underwent right hemihepatectomy. As follows, the

Correspondence to:
Laura Veinberga, lauraveinberga94@gmail.com

cardiovascular stage using cardiopulmonary bypass was successfully performed, removing the TT from the RA and ICV. In the early postoperative period, the patient remained stable and was discharged on the 8th postoperative day. A morphological examination revealed grade 2/3 HCC, a clear cell variant with microvascular and macrovascular invasion. Immunohistochemical staining was positive for HEP-1, CD10, whereas negative for S100. The morphological and immunohistochemical results corresponded to HCC. The treatment of such patients requires the cooperation of various specialties. Although the approach of the surgery is extremely complex including specific technical support, as well as high perioperative risks, the result offers favorable clinical outcomes.

© 2023 The Author(s).

Published by S. Karger AG, Basel

Introduction

Hepatocellular carcinoma (HCC) is the most frequent primary liver tumor, ranking fourth among the leading causes of cancer-related mortality worldwide [1]. The most common type of tumor thrombus (TT) in HCC is in the portal veins (20–65%) [2]. However, TT may also invade hepatic veins, ranging from 1.4 to 4.9%, and also spread to the inferior vena cava (IVC) and the right atrium (RA) (0.67–3%), which is a critical condition [3, 4]. There is no definitive treatment and surgery in this case is extremely challenging. Still, hemihepatectomy with cavoatrial thrombectomy could be considered to exclude the risk of a sudden death. We report a case of advanced HCC with a TT invading into IVC and RA undergoing surgical treatment with hemihepatectomy prior to cavoatrial thrombectomy. The CARE Checklist has been completed by the authors for this case report, attached as online supplementary material [5] (available at www.karger.com/doi/10.1159/000529831).

Case Report/Case Presentation

A 61-year-old man presented with right subcostal pain, progressive weakness, and periodic shortness of breath for 3 months. His past medical history included acute hepatitis A in 1970s and treated hepatitis C in 2014 with no records of current liver cirrhosis. He was diagnosed by contrast-enhanced computed tomography scan with advanced HCC with the TT extending from the IVC to the RA. The right lobe of the liver had extensive malignant formations. The largest formation (14 × 13 × 14 cm) was located in segments 5 to 7. Its volume was calculated to be 1,000 cubic centimeters (cc). Another node (6 × 4.5 × 9 cm) was situated at the level of hepatic venous confluence with an intraluminal mass extending from the right hepatic vein through the IVC to the RA (Fig. 1). The total size of the liver computed tomography imaging dimensions was 28 × 14 × 21 cm. An initial echocardiogram confirmed that TT (2.63 cm) within the RA entering from the IVC had no signs of reaching the tricuspid valve or being that of the pedunculated type (Fig. 2). The atriums and ventricles on both sides were normal in size with a preserved right and left ventricular systolic function. Another important stage prior to surgery included a remnant liver volume calculation to exclude postoperative hepatic insufficiency (Fig. 3; Table 1). The liver functional volume was estimated to be 4,143.6 cc, from which lateral and medial left lobes were 1,355.0 cc (32.7%), whereas medial and lateral right lobes, 2,788.6 cc (67.3%). Therefore, estimated resection volume was 2,788.6 cc, including tumor (1,000 cc), and the estimated remaining liver volume was 1,355.0 cc. Initial laboratory tests revealed serum alpha-fetoprotein 5.37 ng/mL (normal range 0.0–6.0 ng/mL), whereas Child-Pugh class B and albumin-bilirubin (ALBI) grade 2 were calculated (Table 2).

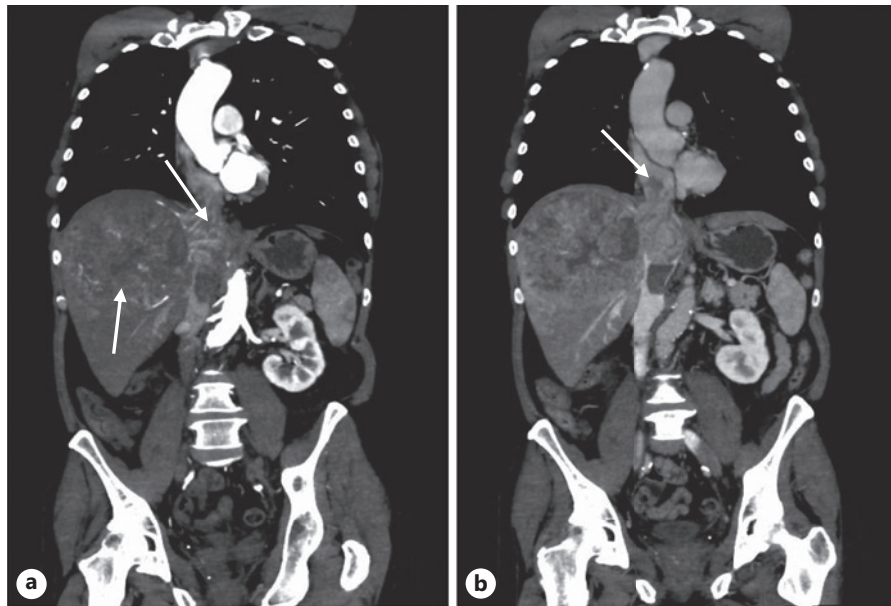


Fig. 1. **a** Arterial-phase CT scan in coronal plane of the thoracic and abdominal cavity showing extensive HCC in the right lobe of the liver with a TT invading the IVC (white arrows). **b** Venous-phase CT scan in coronal plane of thoracic cavity showing TT in RA (white arrow).

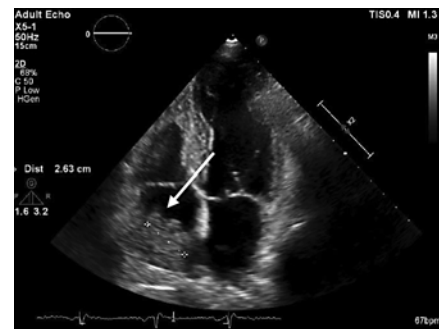


Fig. 2. Preoperative echocardiogram revealed the 2.63 cm mass or thrombus occupying the RA without tricuspid involvement nor being of the pedunculated type (white arrow).

The patient underwent surgical treatment, which lasted 9 h in total. The right hemihepatectomy along with resection of the TT from RA and IVC was executed.

A right subcostal laparotomy was performed. A minimal amount of serous ascites was present, but there were no signs of macroscopic peritoneal dissemination. Visually, the right lobe of the liver parenchyma was extensively enlarged and palpably dense. The most challenging part at the end of right hemihepatectomy involved separation of the closely attached tumor tissue to IVC. During this stage, the IVC was opened and the TT mass was obtained. The right hemihepatectomy was successfully done using the intermittent Pringle maneuver 7 times, each time for 10 min, following a 5-min break. The total Pringle maneuver time exceeded 1 h.

As follows, a median sternotomy was added to the right subcostal laparotomy. Cardiopulmonary bypass was established by cannulating ascending aorta and superior vena cava (SVC). Snares around SVC and IVC were passed. Aortic cross-clamp was applied and antegrade crystalloid cardioplegia was administered. Snare around SVC was tightened and right atriotomy was performed, exposing access to tumor masses that were removed from RA. Intermittently tightening the snare around, reachable masses from IVC were removed. After this stage, the snare around IVC was tightened to prevent possible further embolization in

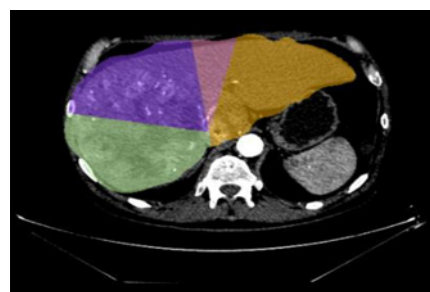


Fig. 3. Remnant liver volume: arterial-phase CT scan in axial plane of abdominal cavity showing computed functional volume of liver segments.

Table 1. Functional liver volume calculation

Liver		
Liver	Volume	% out of total
Functional liver	4,143.6 cc	100.0
Total liver	4,143.6 cc	100.0
Segments		
Segments	Functional volume	% out of functional
■ Lateral left lobe	1,021.6 cc	24.7
■ Medial left lobe	333.4 cc	8.0
■ Medial right lobe	1,625.0 cc	39.2
■ Lateral right lobe	1,163.6 cc	28.1
	1,355.0 cc	32.7
	2,788.6 cc	67.3

Table 2. Initial laboratory test results

WBC	6.55×10 ⁹ /L	Total bilirubin	88.9 μmol/L ↑
RBC	5.47×10 ¹² /L	Direct bilirubin	76.6 μmol/L ↑
Hemoglobin	165 g/L	Lipase	40.9 U/L
Hematocrit	49.6%	Alpha-amylase	57 U/L
Platelet count	169×10 ⁹ /L	Creatinine	60 μmol/L ↓
Prothrombin activity	68%	Total protein	62.1 g/L ↓
INR	1.19	Albumin	32.1 g/L ↓
aPTT	44.4 s ↑	Sodium	134 mmol/L
ALT	45 U/L ↑	Potassium	3.95 mmol/L
AST	118 U/L ↑	CRP	44.4 mg/L ↑
ALP	266 U/L ↑	Procalcitonin	0.146 ng/mL ↑
BUN	5.43 mmol/L	AFP	5.37 ng/mL

next stage, and RA was deaired and closed. An aortic cross-clamp was released after 21 min. This was followed by opening of the IVC and removal of the remaining tumor masses. The IVC was closed and snare around IVC was released. Cardiopulmonary bypass was discontinued and canules were removed. Total cardiopulmonary bypass time was 62 min.

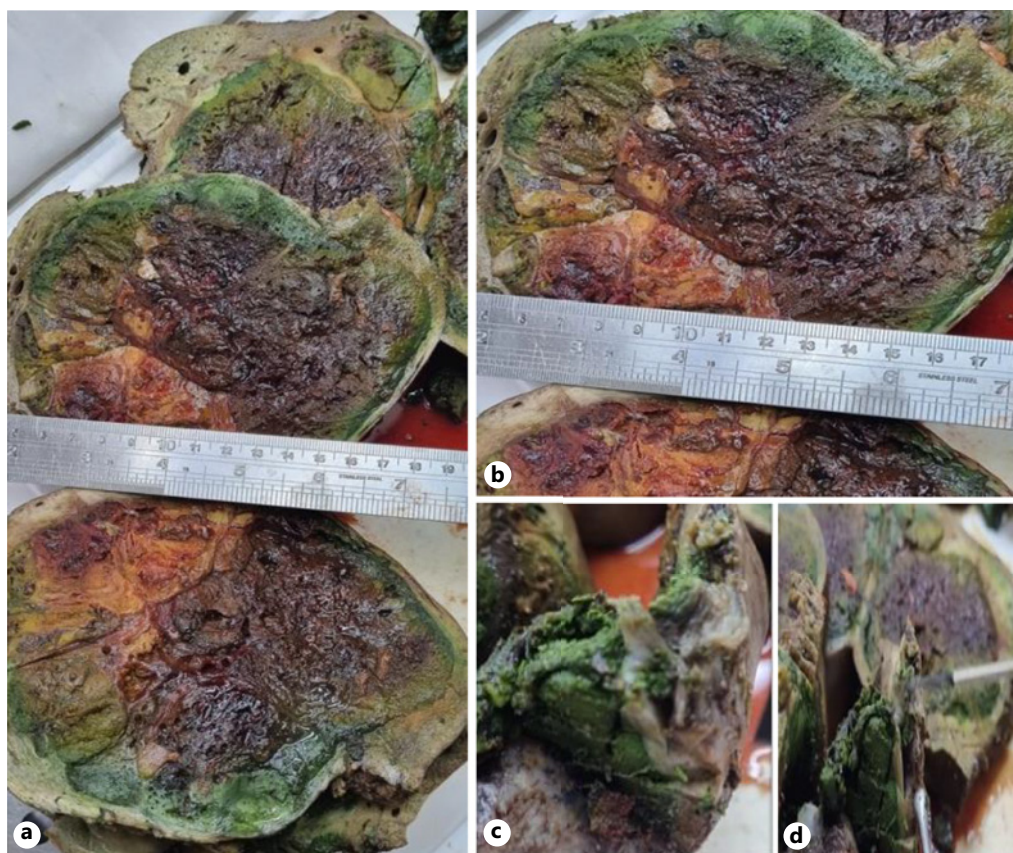


Fig. 4. Operative specimens. **a, b** Gross view of the tumor. **c, d** Tumor growth into large veins in gross examination.

The resected liver was $22 \times 14 \times 10 \times 14$ cm with multiple yellowish-pale nodules in diameter 0.5–13 cm. The largest of them was $13 \times 11 \times 14$ cm (Fig. 4).

Microscopic examination of the resected tumor revealed multifocal grade 2/3 HCC, clear cell variant with the microvascular and macrovascular invasion (Fig. 4). Two lymph nodes (0.6 and 1.1 cm) sent for pathohistological examination showed reactive sinus histiocytosis with no elements of tumor. Immunohistochemical staining was positive for HEP-1 and CD10: immunohistochemical markers of HCC. It was negative for S100: immunohistochemical markers of liver cirrhosis. Ki-67 proliferation fraction showed rates from 5% to 25% in malignant HCC cells (Fig. 5). Based on these findings, we confirmed the diagnosis of the HCC with the microvascular and macrovascular invasion and a TT extending from the IVC to the RA.

In the early postoperative course, the patient remained stable and was discharged on the 8th postoperative day. After the surgery, the patient remained under supervision of the oncologist, the hepatobiliary surgeon, and the radiologist. After 7 months of follow-up, the patient is still alive and in good condition.

Discussion/Conclusion

HCC with TT extension through the hepatic veins and IVC into the RA is reported in up to 3% of all cases [3, 4]. Besides, studies have reported even a higher rate (4.1%) upon autopsy for patients without previously known diagnosis of HCC and TT reaching RA [6, 7].

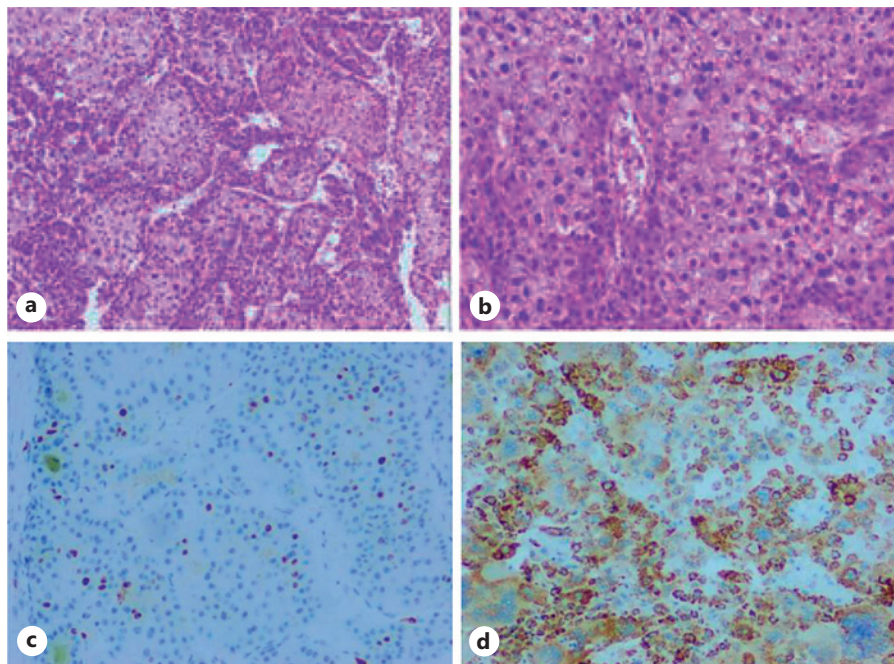


Fig. 5. Pathological findings of HCC, clear cell (CC) variant. **a** Hematoxylin and eosin (HE) stain, original magnification (OM), $\times 40$. **b** HCC, CC variant, HE stain, OM, $\times 100$. Immunohistochemical findings of HCC. **c** HCC proliferation activity with Ki67, immunoperoxidase, OM, $\times 100$. **d** HCC, CC variant, immunoperoxidase (HepPar1), OM, $\times 100$.

This condition is considered to be an advanced stage of the disease with the mortality rate up to 25% due to sudden death caused by various complications [8]. Examples would include pulmonary embolism, occlusion of the tricuspid valve, lung metastasis, pulmonary infarction, secondary Budd-Chiari syndrome, ball-valve thrombus syndrome, and heart failure [8]. Although there is no definitive treatment for the condition, surgery in patients with a sufficient hepatic reservoir is still indicated due to the risk of sudden death from the complications mentioned before.

Current literature describes two possible orders for the procedure, either beginning with the hemihepatectomy before the cavo-atrial TT resection or starting with the cavo-atrial TT resection before the hemihepatectomy. The general consensus is to start with the hemihepatectomy due to the high risk of bleeding after the administration of heparin required for the cavo-atrial TT resection. However, in cases where the TT in the RA reaches the tricuspid valve and is of the pedunculated type, it is advised to start with the cavo-atrial TT resection due to the increased risk of the ball-valve effect or a pulmonary embolism leading to sudden cardiac arrest during surgery [9]. In our case, the echocardiogram did not show TT reaching the tricuspid valve nor being of the pedunculated type; therefore, we decided to begin with right hemihepatectomy. As follows, cardiovascular stage using cardiopulmonary bypass was successfully performed, removing the TT from the RA and IVC. Although very few studies yield surgical outcomes, Matsukuma et al. [10] reported postoperative complications including pulmonary artery embolism, ascites, pleural effusion, arrhythmia, bile leak, and surgical-site infection.

Overall, hemihepatectomy with cavo-atrial thrombectomy is challenging; however, recent surgical innovations and the advanced surgeons' skill set have improved the safety of this procedure. A study performed by Wakayama and colleagues [11] yielded 6 patients undergoing liver resection combined with removal of IVC and RA thrombi with no

postoperative mortality. Also, Matsukuma and co-authors [10] reported 13 patients after liver resection and cavo-atrial thrombectomy. No in-hospital deaths were reported. However, the prognosis for patients after the surgery is still considered to be poor. In literature, median overall survival (OS) time varies from 11.2 to 36.4 months with median disease-free survival time of 9 months [6, 7, 12, 13]. To further improve OS after surgery, more studies assessing the effect of different treatment modalities are necessary. Kasai et al. [14] reported an effective response to hepatic arterial injection chemotherapy prior to surgery for patients with advanced IVC TT when compared with no hepatic arterial injection chemotherapy (median survival time: unreached vs. 8.3 months, $p = 0.007$). Therefore, it could be an encouraging option for patients with HCC TT invading RA. Nevertheless, when surgery is not feasible, other therapeutic approaches are also available (e.g., radiotherapy, transarterial chemoembolization, symptomatic treatment) with reported median survival time being only 4.5–10 months [15–17]. Therefore, these data are indicating surgery might result in better survival when comparing to other nonsurgical treatments.

The patient in our case remained under supervision of an oncologist, a hepatobiliary surgeon, and a radiologist. He was assigned to sorafenib, which is a standard of systemic treatment for patients with advanced HCC and well-preserved liver function (Child-Pugh A class). It has proved to increase survival rate up to 1 year in patients with advanced HCC [18]. However, recently it was reported that atezolizumab and bevacizumab combination therapy demonstrated a significant OS benefit compared with sorafenib alone with a hazard ratio for death of 0.66 (95% confidence interval: 0.52–0.85; p (1/4) = 0.0009) in data reported by Finn and colleagues [19]. Unfortunately, in our case, the patient did not accept sorafenib due to the side effects it caused. Despite that, he did not show any clinical signs or symptoms of recurrence during follow-up 7 months after the surgery.

In conclusion, we have reported a case with HCC TT invading the RA. Although the approach of the surgery is extremely complex and requires the cooperation of various specialties, the result offers good clinical outcomes. Therefore, other colleagues may benefit from our experience when treating similar patients in the future.

Statement of Ethics

The study was conducted according to the guidelines of the Declaration of Helsinki. The study protocol was reviewed and approved by the Research Ethics Committee at Pauls Stradins Clinical University Hospital Development Society (Approval No. 021121-2L, 02 November 2021). Written informed consent was obtained from the patient for the publication of the details of patient's medical case and any accompanying images.

Conflict of Interest Statement

The authors declare that the research was conducted in the absence of any commercial or financial relationships that could be construed as a potential conflict of interest.

Funding Sources

None of the authors received any funding.

Author Contributions

Conceptualization: Arturs Ozolins and Armands Sivins; methodology: Janis Vilmanis; validation: Arturs Ozolins, Peteris Stradins, and Marcis Gedins; formal analysis and supervision: Arturs Ozolins; investigation: Edgars Zellans, Juris Berzins, Maija Radzina, and Inese Briede; resources: Kristians Meidrops, Deniss Anufrijevs, Juris Berzins, Inese Briede, Inguna Krustina, and Karina Drizlionoka; data curation: Arturs Ozolins and Laura Veinberga; writing – original draft preparation: Laura Veinberga and Kristians Meidrops; project administration and writing – review and editing: Arturs Ozolins and Peteris Stradins; and visualization: Juris Berzins, Maija Radzina, and Inese Briede.

Data Availability Statement

The data presented in this study are available on request from the corresponding author. The data are not publicly available yet due to ongoing research.

References

- 1 Llovet JM, Villanueva A, Marrero JA, Schwartz M, Meyer T, Galle PR, et al. Trial design and endpoints in hepatocellular carcinoma: AASLD consensus conference. *Hepatology*. 2021;73(Suppl 1):158–91
- 2 Huang J, Pan ZY, Li L, Jiang BG, Gu FM, Wang ZG, et al. Hepatocellular carcinoma with inferior vena caval and right atrial tumor thrombi and massive pulmonary artery embolism: a case report. *Mol Clin Oncol*. 2017;6(1):111–4.
- 3 Zhang YF, Wei W, Guo ZX, Wang JH, Shi M, Guo R. Hepatic resection versus transcatheter arterial chemoembolization for the treatment of hepatocellular carcinoma with hepatic vein tumor thrombus. *Jpn J Clin Oncol*. 2015;45(9):837–43.
- 4 Luo F, Li M, Ding J, Zheng S. The progress in the treatment of hepatocellular carcinoma with portal vein tumor thrombus. *Front Oncol*. 2021;11:635731.
- 5 Riley DSBM, Barber MS, Kienle GS, Aronson JK, von Schoen-Angerer T, Tugwell P, et al. CARE guidelines for case reports: explanation and elaboration document. *J Clin Epidemiol*. 2017;89:218–35.
- 6 Luo X, Zhang B, Dong S, Zhang B, Chen X. Hepatocellular carcinoma with tumor thrombus occupying the right atrium and portal vein: a case report and literature review. *Medicine*. 2015;94(34):e1049.
- 7 Wassef J, Xu S. Hepatocellular carcinoma with tumor thrombus to the hepatic veins and the right atrium: a case report and review exploring various presentations and treatment options. *Cureus*. 2020;12(6):e8405.
- 8 Hamano G, Takemura S, Tanaka S, Shinkawa H, Aota T, Fujii H, et al. Intrahepatic cholangiocarcinoma with a tumor thrombus extending from the inferior vena cava to the right atrium: a case report. *Surg Case Rep*. 2021;7(1):3.
- 9 Ariizumi SI, Kotera Y, Omori A, Kikuchi C, Tokitou F, Yamashita S, et al. Cavo-atrial thrombectomy prior to hepatectomy for hepatocellular carcinoma with tumor thrombus in the right atrium: a case report. *Surg Case Rep*. 2019;5(1):57.
- 10 Matsukuma S, Eguchi H, Wada H, Noda T, Shindo Y, Tokumitsu Y, et al. Liver resection with thrombectomy for patients with hepatocellular carcinoma and tumour thrombus in the inferior vena cava or right atrium. *BJSO*. 2020;4(2):241–51.
- 11 Wakayama K, Kamiyama T, Yokoo H, Kakisaka T, Kamachi H, Tsuruga Y, et al. Surgical management of hepatocellular carcinoma with tumor thrombi in the inferior vena cava or right atrium. *World J Surg Oncol*. 2013;11:259.
- 12 Qiu W, Wang C, Zhang R, Wei F, Shi X, Sun X, et al. Surgical treatment of a rare case of hepatocellular carcinoma with right atrial metastasis: a case report. *Medicine*. 2020;99(32):e21630.
- 13 Lemekhova A, Hornuss D, Polychronidis G, Mayer P, Rupp C, Longerich T, et al. Clinical features and surgical outcomes of fibrolamellar hepatocellular carcinoma: retrospective analysis of a single-center experience. *World J Surg Oncol*. 2020;18(1):93.
- 14 Kasai Y, Hatano E, Seo S, Taura K, Yasuchika K, Okajima H, et al. Proposal of selection criteria for operative resection of hepatocellular carcinoma with inferior vena cava tumor thrombus incorporating hepatic arterial infusion chemotherapy. *Surgery*. 2017;162(4):742–51.
- 15 Lou J, Li Y, Liang K, Guo Y, Song C, Chen L, et al. Hypofractionated radiotherapy as a salvage treatment for recurrent hepatocellular carcinoma with inferior vena cava/right atrium tumor thrombus: a multi-center analysis. *BMC Cancer*. 2019;19(1):668.

- 16 Wang Y, Yuan L, Ge RL, Sun Y, Wei G. Survival benefit of surgical treatment for hepatocellular carcinoma with inferior vena cava/right atrium tumor thrombus: results of a retrospective cohort study. *Ann Surg Oncol*. 2013; 20(3):914–22.
- 17 Fleckenstein FN, Jonczyk M, Can E, Lüdemann WM, Savic L, Maleitzke T, et al. Hepatocellular carcinoma tumor thrombus entering the right atrium treated with combining percutaneous and intravenous high-dose-rate brachytherapy: a case report. *CVIR Endovasc*. 2021;4(1):71.
- 18 Longo L, de Freitas LBR, Santos D, Grivicich I, Álvares-da-Silva MR. Sorafenib for advanced hepatocellular carcinoma: a real-life experience. *Dig Dis*. 2018;36(5):377–84.
- 19 Finn RS, Qin S, Ikeda M, Galle PR, Ducreux M, Kim TY, et al. IMbrave150: updated overall survival (OS) data from a global, randomized, open-label phase III study of atezolizumab (atezo) + bevacizumab (bev) versus sorafenib (sor) in patients (pts) with unresectable hepatocellular carcinoma (HCC). *J Clin Oncol*. 2021; 39(3_Suppl 1):267.