

The expression of cytokines and β –defensin 2, - 3, -4 in rabbit bone tissue after hydroxyapatite (HAp), α -Tricalcium phosphate (α -TCP) and polymethylmethacrylate (PMMA) implantation

J Vamze^{1,3}, M Pilmane¹, A Skagers²

¹Riga Stradins University, Institute of Anatomy and Anthropology, Kronvalda 9, LV-1010, Riga, Latvia

²Riga Stradins University, Department of Oral and Maxillofacial Surgery, Dzirciema 20, LV-1007, Riga, Latvia

E-mail: j.vamze@inbox.lv

Abstract Bone loss induced by inflammation is one of the complications after biomaterial implantation. There is no much data on expression of cytokines and defensins into the bone tissue around the implants in literature. The aim of this work was to investigate the distribution and appearance of interleukin (IL)-1, IL-6, IL-8, IL-10 and β – defensin (BD)-2, BD-3, BD-4 after the implantation of different biomaterials. Bone developing zones, signs of bone-implant contact and low expression of pro-inflammatory cytokine IL-1, IL-6 and anti-inflammatory cytokine IL-10 in experimental tissue with pure HAp and unburned HAp implants indicate a potential advantage of this material in terms of its biocompatibility over the other materials used in our study.

1. Introduction

Bone loss induced by inflammation is one of the complications after biomaterial implantation into the hard tissue. Pro-inflammatory cytokines interleukin-1 (IL-1) and interleukin-6 (IL-6) exhibit a pro-osteoclastogenic effect in response to implant-derived wear particles. IL-6 recruits and activates osteoclasts and may therefore leads to bone resorption and the loss of implant fixation [1]. Interleukin (IL-8) has been described as a pro-inflammatory mediator in gingivitis [2]. Interleukin-10 (IL-10) is an anti-inflammatory cytokine with pleiotropic effect on immunoregulation and inflammation [3]. The role of β – defensin (BD)-1, BD-2, BD-3 in immune defence against oral infection in cases of biomaterial implantation is not completely defined. There are varying data regarding the expression of cytokines and defensins into the bone tissue around the different bioceramic implants is little discussed.

³ To whom any correspondence should be addressed

The aim of this experiment was to research changes in distribution and appearance of pro-inflammatory cytokines and anti-inflammatory proteins in the lower jaw and tibial bone of experimental rabbits 3 months after the implantation of different biomaterials.

2. Material and methods

The Animal Ethics Committee of Latvian Food and Veterinary Administration approved the use of 4 Californian male rabbits for this morphofunctional study. Commercial biomaterial and biomaterials produced in Riga Technical University Biomaterial Innovation and Development centre were used in the experiment.

The rabbits received general anaesthesia with Sol. Ketamini (15 mg/kg) and Sol. Dormicum (2 mg/kg), local anaesthesia with Sol. Midazolami (0.5 mg/kg) and Sol. Articaini (5 mg/kg). After raising mucoperiosteal flap, the channel was drilled using 2.0 mm diameter trephine and intraosseal implantation of the following biomaterials were performed: pure hydroxyapatite (HAp) tablet, HAp tablet covered by polycaprolactone (PCL), unburned HAp granules, HAp granules burned under 1150⁰C, commercial polymethylmethacrylate (PMMA) bone cement (Biomet Bone Cement R), PMMA cement, α -Tricalcium phosphate (α -TCP) cement I with pH6 and α -TCP cement II with pH7. The control site was similarly prepared and closed but no biomaterials were inserted.

Three months afterwards, the euthanasia of rabbits was performed by air embolisation and blocks of bone and soft tissue were harvested from experimental and control sites using diamond disc. Tissue were embedded into the paraffin, cut into 5 μ m thick slices and prepared for detection of the interleukins: interleukin-1 (IL-1, working dilution 1:1000, abcam, UK), interleukin-6 (IL-6, working dilution 1:50, Santa Cruz Biotechnology, Inc), interleukin-8 (IL-8, working dilution 1:50, Santa Cruz Biotechnology, Inc), interleukin-10 (IL-10, working dilution 1:400, abcam, UK) using biotin-streptavidin immunohistochemistry (IHC) [4]. Innate immunity in rabbits' bones was detected by β – defensin 2 (BD-2, working dilution 1:100, RD systems, UK), β defensin 3 (BD-3, working dilution 1:100, Life Span Biosciences), β defensin 4 (BD-4, working dilution, 1:150, Santa Cruz Biotechnology, Inc) using IHC. Routine staining for haematoxylin and eosin (H/E) was performed for each case [5]. Structure quantification was done applying the semi – quantitative counting method [6].

3. Results

Routine histological examination revealed bone developing zones and signs of bone-implant contact in the experimental tissue with such biomaterials as pure HAp, HAp tablet covered by PCL, commercial PMMA bone cement and unburned HAp granules (Figure 1). In bone tissue samples with α -TCP cements biomaterial, the regions of ossification were less pronounced but in tissue with uncommercial PMMA cement, the ossification zones were not detected at all. Expression of defensins and interleukins in the experimental and control tissue was variable. Marked expression of BD-2 and BD-3 was observed in the tissue with pure HAp (Figure 2).

BD-4 (β -defensin-4) expression was more pronounced in the tissue with commercial PMMA bone cement (Figure 3) and with HAp covered by PCL. Large number of IL-1 positive cells were noticed in tissue with both types of PMMA, α -TCP cement I and HAp tablets covered by PCL, whereas a low expression of IL-1 was detected in control tissue. Little difference in number was found between IL-6 and IL-1 positive bone cells. IL-6 positive osteocytes in tissue with uncommercial PMMA cement were detected in less amount but in tissue with burned HAp granules (Figure 4), IL-6 positive cells were found more than IL-1 positive osteocytes.

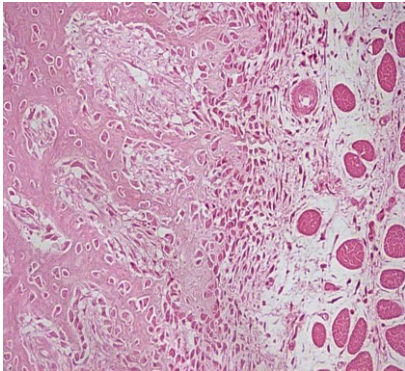


Figure 1. Bone developing zones in tissue using unburned HAp granules; H/E, x250

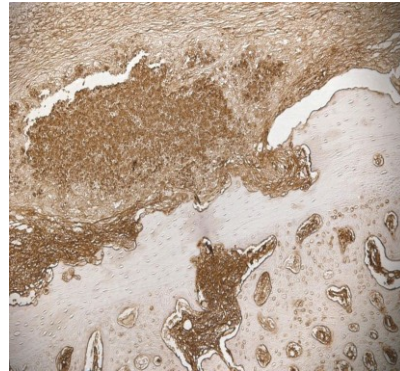


Figure 2. Large number of BD-3 positive osteocytes in bone tissue with pure HAp biomaterial; IHC, x200

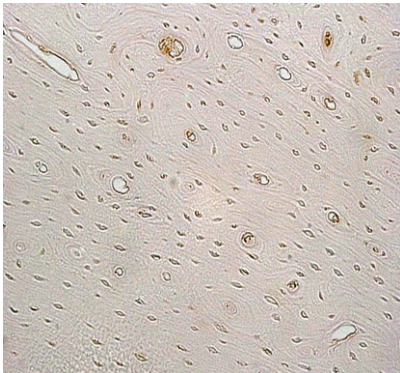


Figure 3. Large number of BD-4 positive osteocytes in bone tissue with commercial PMMA cement; IHC, x250

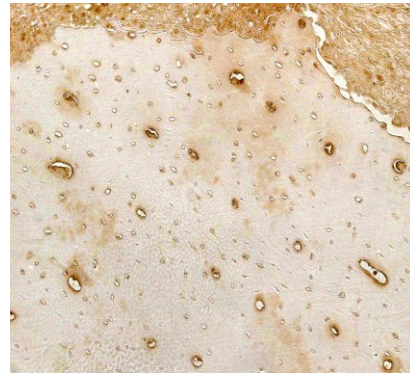


Figure 4. Moderate number of IL-6 positive osteocytes in bone tissue with HAp granules; IHC, x250

However, control tissue showed a significant number of IL-6 positive cells. Low expression of IL-8 was noticed in all experimental (Figure 5) and control tissue, except in the case of commercial PMMA bone implant where IL-8 positive osteocytes were detected in moderate number. Large number of IL-10 positive osteocytes were detected in experimental tissue with HAp tablets covered by PCL (Figure 6), commercial PMMA cement and α -TCP bone cement I.

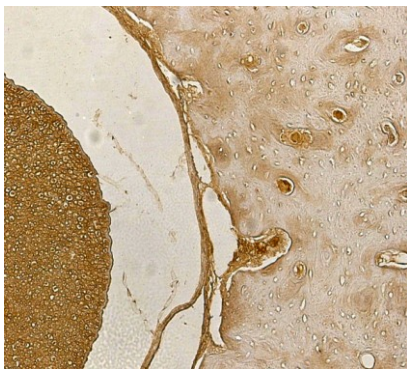


Figure 5. Some IL-8 positive osteocytes in bone tissue with burned HAp granules; IHC x200

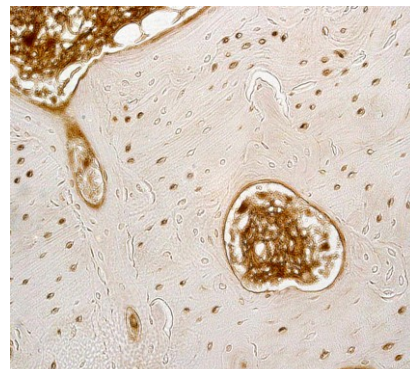


Figure 6. Large number of IL-10 positive osteocytes in bone tissue with HAp covered by PCL; IHC, x250

4. Discussion

Our experimental study showed that biomaterials such as commercial PMMA cement, HAp covered by PCL and α -TCP cement I influence the increase in the expression of IL-10 and IL-6. Weak expression of IL-10 we revealed in experimental tissue with pure and unburned HAp material. As IL-10 is true anti-inflammatory cytokine, its absence suggests the absence of inflammation in the bone. However, any variation of IL-10 level should be evaluated as individual response from host tissue. The research of Ninomiya (2001) demonstrates that HAp and HA/TCP (hydroxyapatite/tricalcium phosphate) particles are capable of stimulating the expression and secretion of cytokines IL-6 and proteases that increase bone resorption [7].

The augmentation in IL-8 expression was revealed only in bone tissue with commercial PMMA, whereas in the experiment with other biomaterials it was very weak. The expression of pro-inflammatory cytokine IL-1 in our experimental material was similarly distinct in both commercial and uncommercial PMMA bone cements, α -TCP cement (pH6) and HAp tablet covered by PCL. IL-1 is essential protein for the bone resorption but IL-8 is suggested to be less potential for this function [8].

β -defensins 1-3 were first described in the osteoblast cell cultures [9] with dominance of defensin 1 and 2. With regard to the reaction of BD-2, BD-3 and BD-4 in our study, the activity was varying. We suggest a role of defensins in traumatic injury could be important in case of biomaterial implantation in the bone.

5. Conclusion

Bone developing zones, signs of bone-implant contact and low expression of pro-inflammatory cytokine IL-1, IL-6 and anti-inflammatory cytokine IL-10 in experimental tissue with pure HAp and unburned HAp implants indicate a potential advantage of this material in terms of its biocompatibility over the other materials used in our study.

References

- [1] Holt G, Murnaghan C, Reilly J, Meek R M 2007 *Clin Orthop Relat Res.* **460** 240
- [2] Haake S K, Huang G T J 2002 Molecular Biology of the host-Microbe Interaction in Periodontal Diseases (Selected Topics) In: Newman, Takei, Carranza, eds. *Clinical Periodontology*, Philadelphia: W.B.Saunders Co 162
- [3] Eskdale J, Kube D, Tesch H, Gallagher G 1997 *Immunogenetics* **46** 120
- [4] Hsu S M, Raine L, Fanger H 1981 *J Histochem Cytochem* **29** 577
- [5] Kiernan J A 2008 *Histological and Histochemical Methods: Theory and Practice* In: Bloxham, UK: Scion 141–174
- [6] Pilmane M, Luts A, Sundler F 1995 *Thorax* **50** 551
- [7] Ninomiya J T, Struve J A, Stelloh C T, Toth J M, Crosby K E 2001 *J Orthop Res.* **19** 621
- [8] Schmidt C, Steinbach G, Decking R, Claes L E, Ignatius 2003 *Biomaterials* **24** 4191
- [9] Bissell J, Joly S, Johnson G K, Organ C C, Dawson D, McCray P B, Guthmiller J M 2004 *J Oral Pathol Med* **33** 278